

Dr. Mario Rotella

MY DENTAL PORTFOLIO

*Showcasing some of
my work...*



ABOUT ME



I want to provide my patients the confident and healthy smiles they deserve.

I am a Fellow of the Royal College of Dentists of Canada (F.R.C.D.(C)), board certified specialist in Prosthodontics.

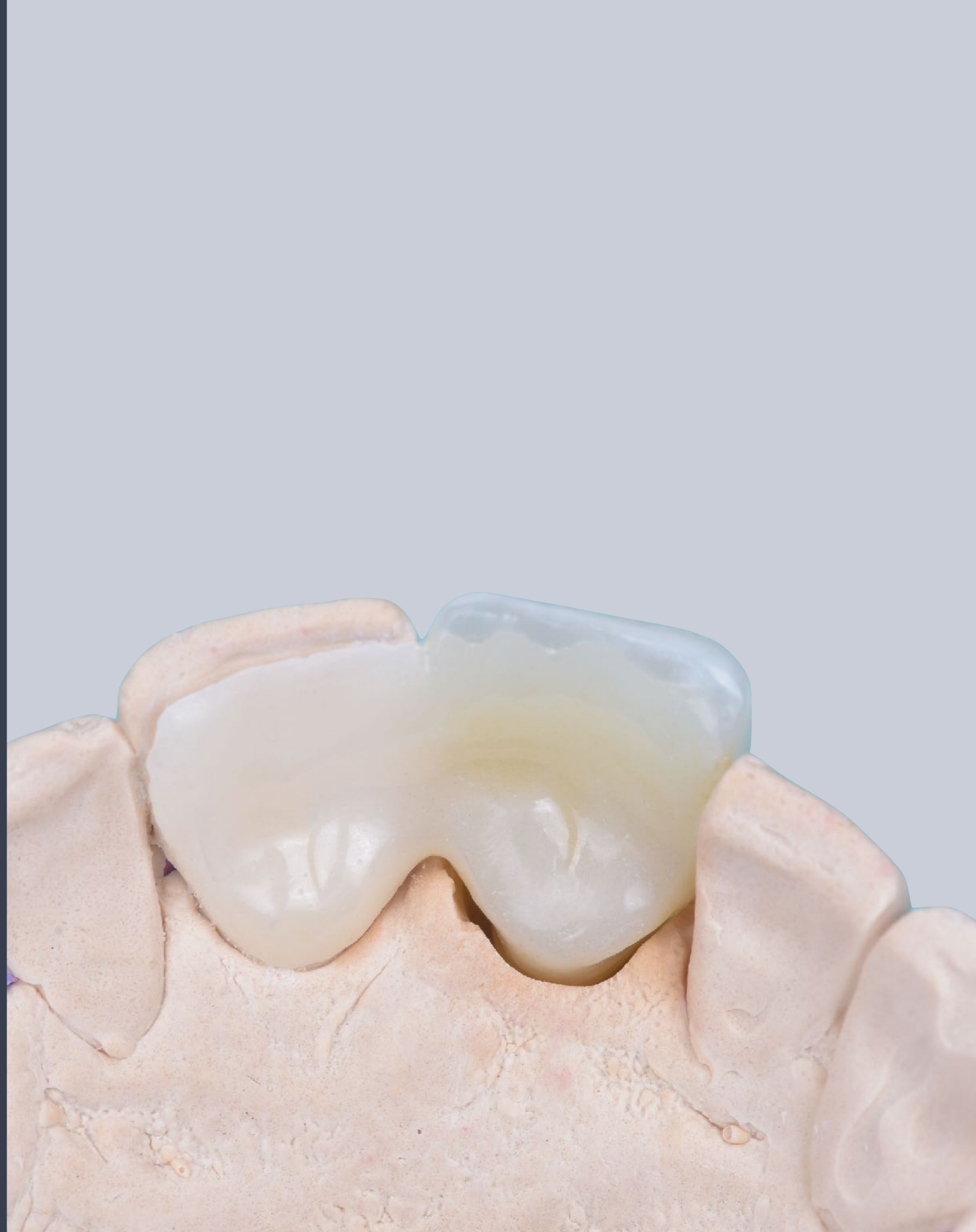I received my Doctor of Dental Surgery from the University of Siena (Italy), where I graduated with *summa cum laude*.

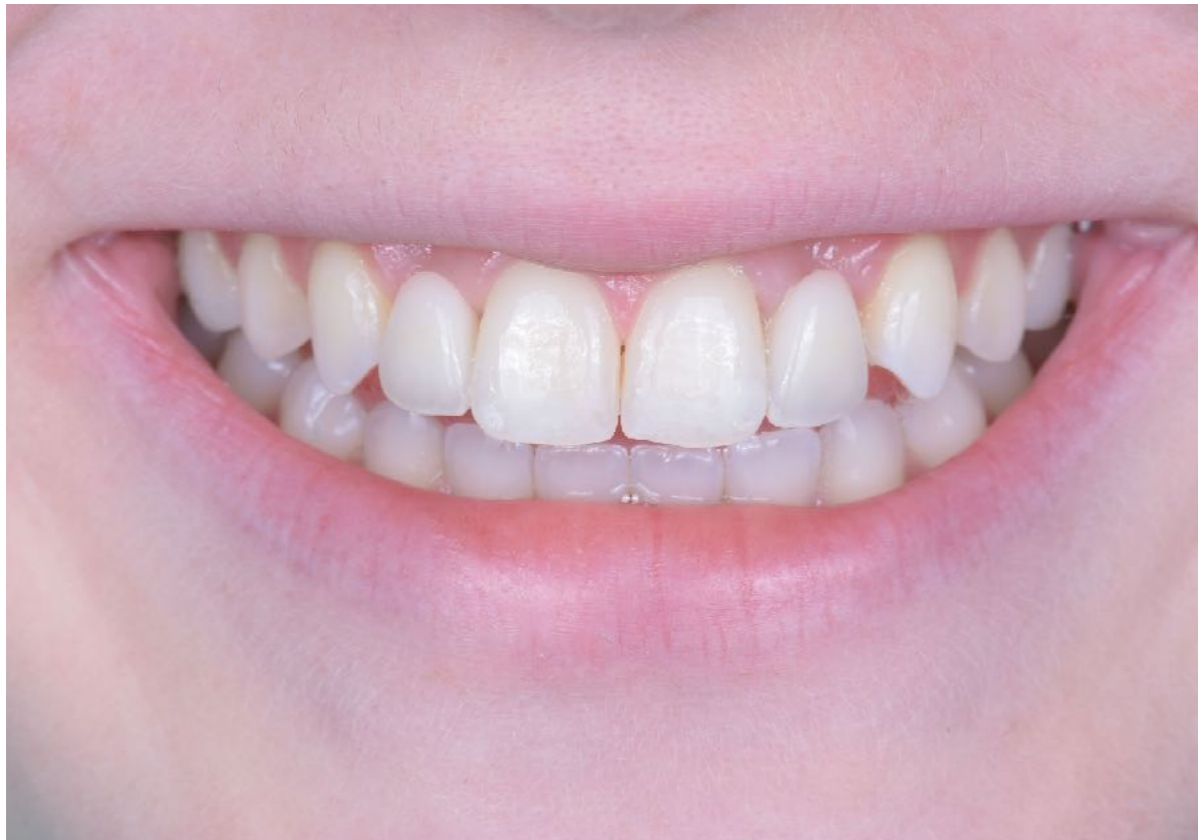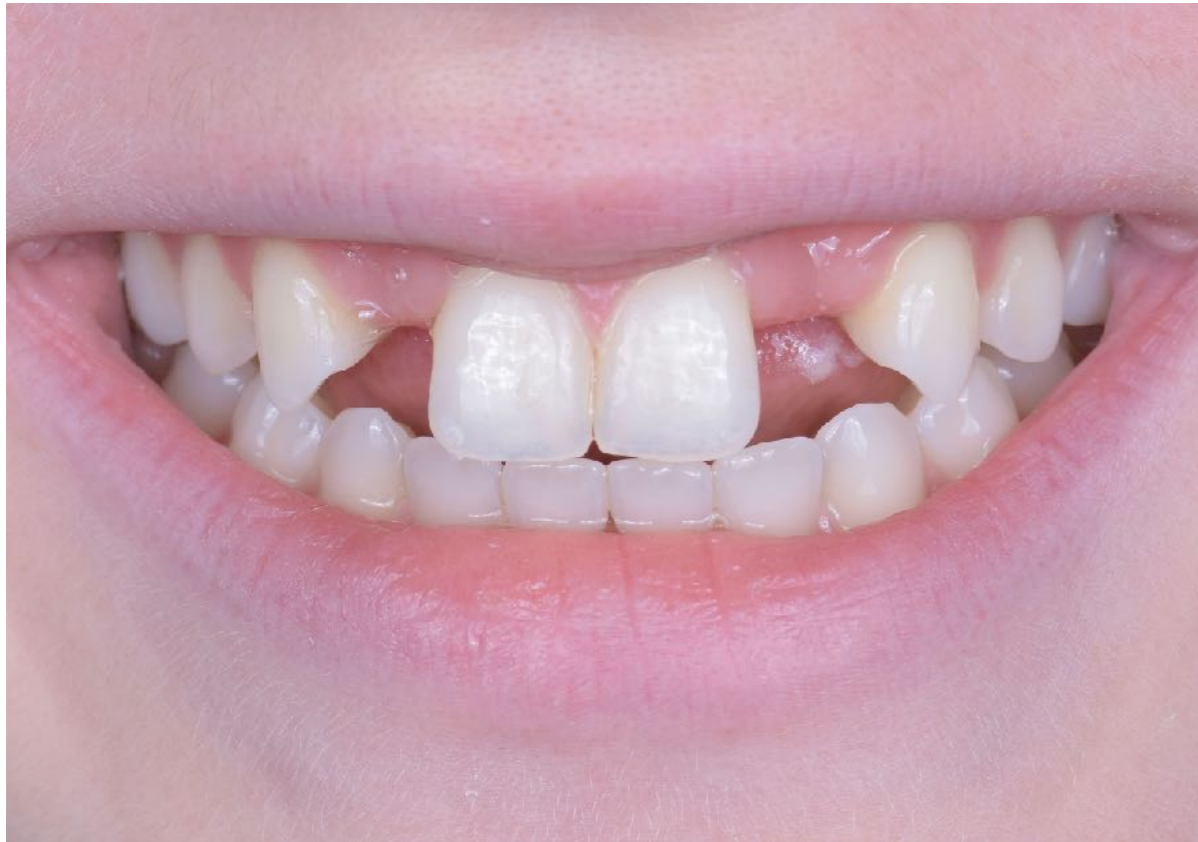I completed a 2-year Advance Education in General Dentistry program at the Eastman Institute for Oral Health, University of Rochester, Rochester, NY. At the same institution, I completed a 3-year Prosthodontic program.

I focus my practice concentrating on the treatment of complex cases of aesthetic and functional rehabilitation on natural dentition and implants, with emphasis on veneers, crowns, bridges and dentures.

MARYLAND BRIDGES

- It includes a floating tooth to replace the missing one, but it adheres to the adjacent teeth in a unique way. Specifically, with 1 wing reaching out on one side to bond to the back side of the supporting tooth
- Call it bonded bridge; It is a perfect replacement for missing 1 front tooth, especially in young patients





Missing 2 upper lateral teeth

You can imagine how hard is for anyone, but especially for a young individual to have 2 front teeth missing!

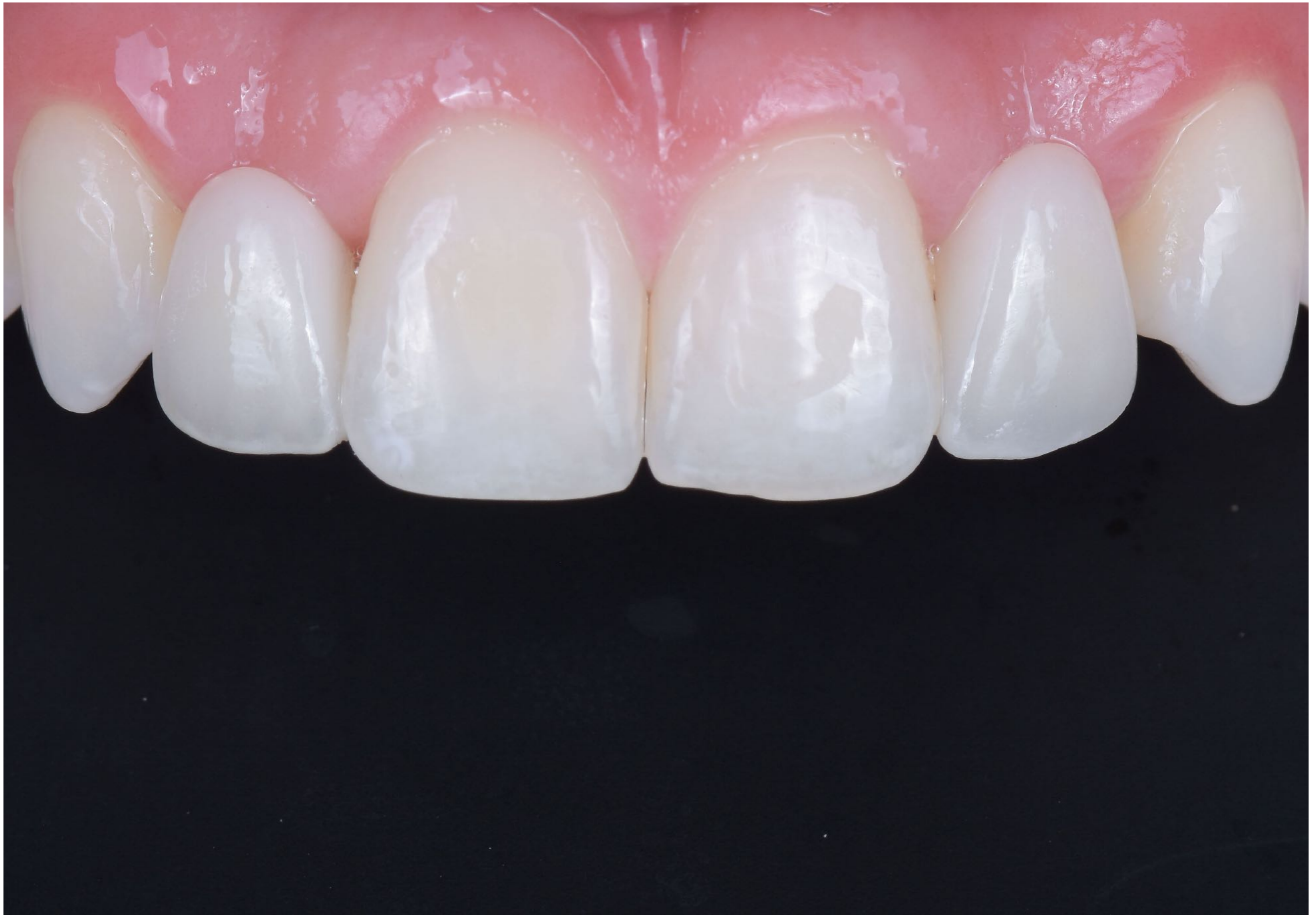In general, dental implants are the “best” option to replace missing teeth.

However in some situations, due to cost or the patient’s age, implants are not a viable option.

Thus, bonded bridges are a great alternative to replace these missing teeth.

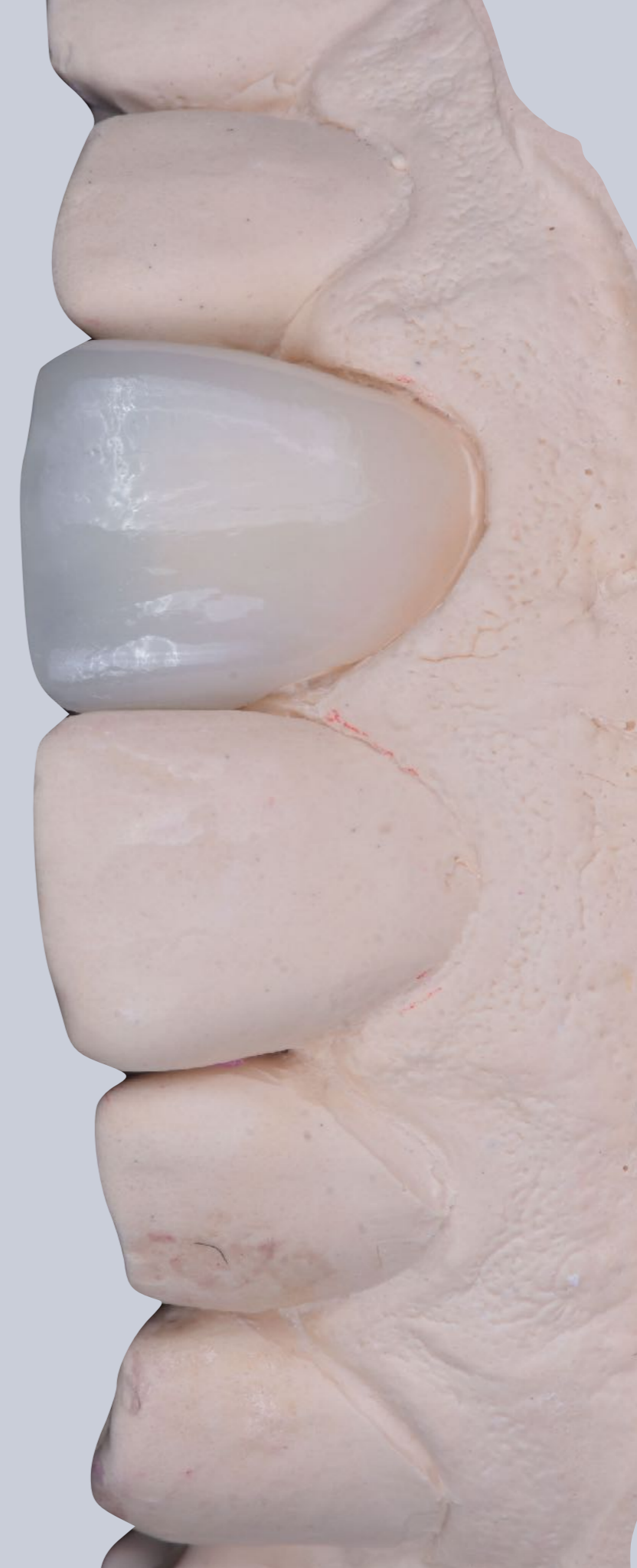Main advantages include:

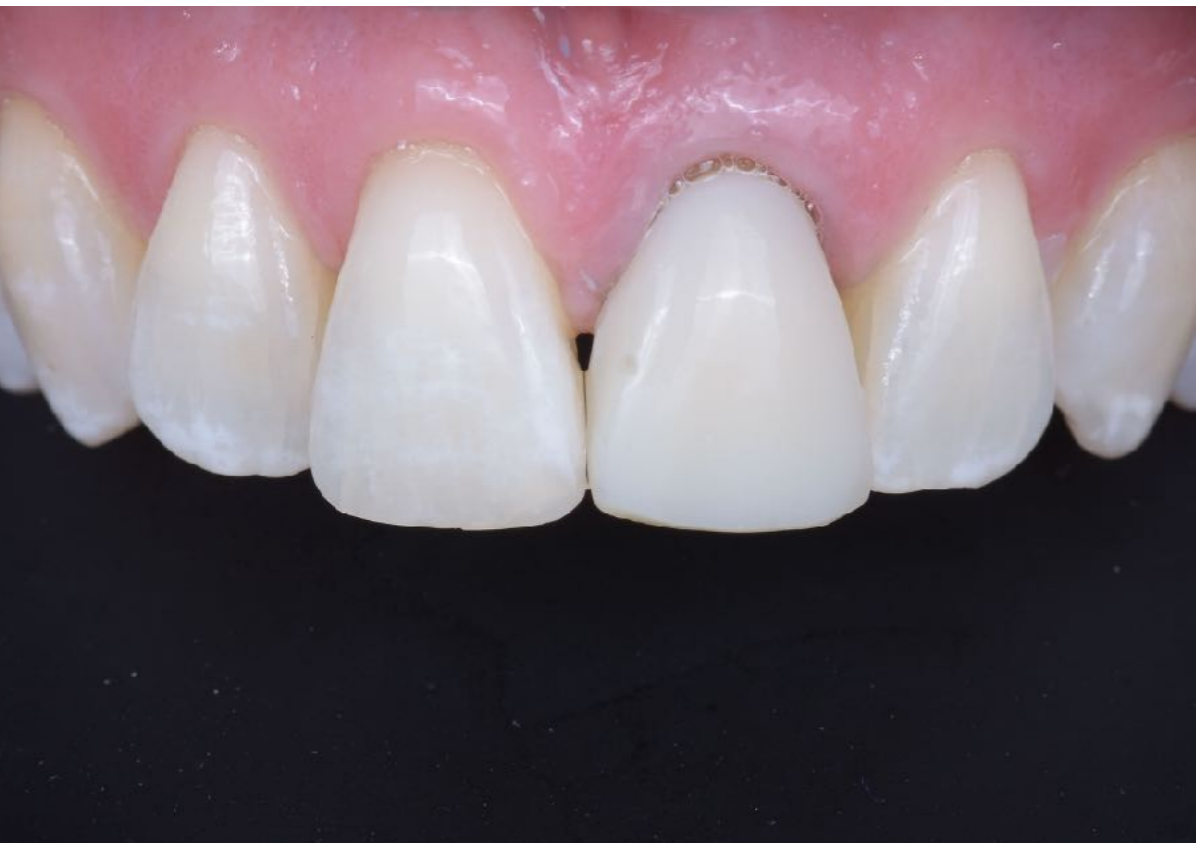- Conservative, since minimal or no tooth preparation is required
- Aesthetics: smile can be restored boosting the patient’s confidence
- Time: in general only 2 appointments are required to complete the treatment
- Cost: this is a less expensive option than dental implants.



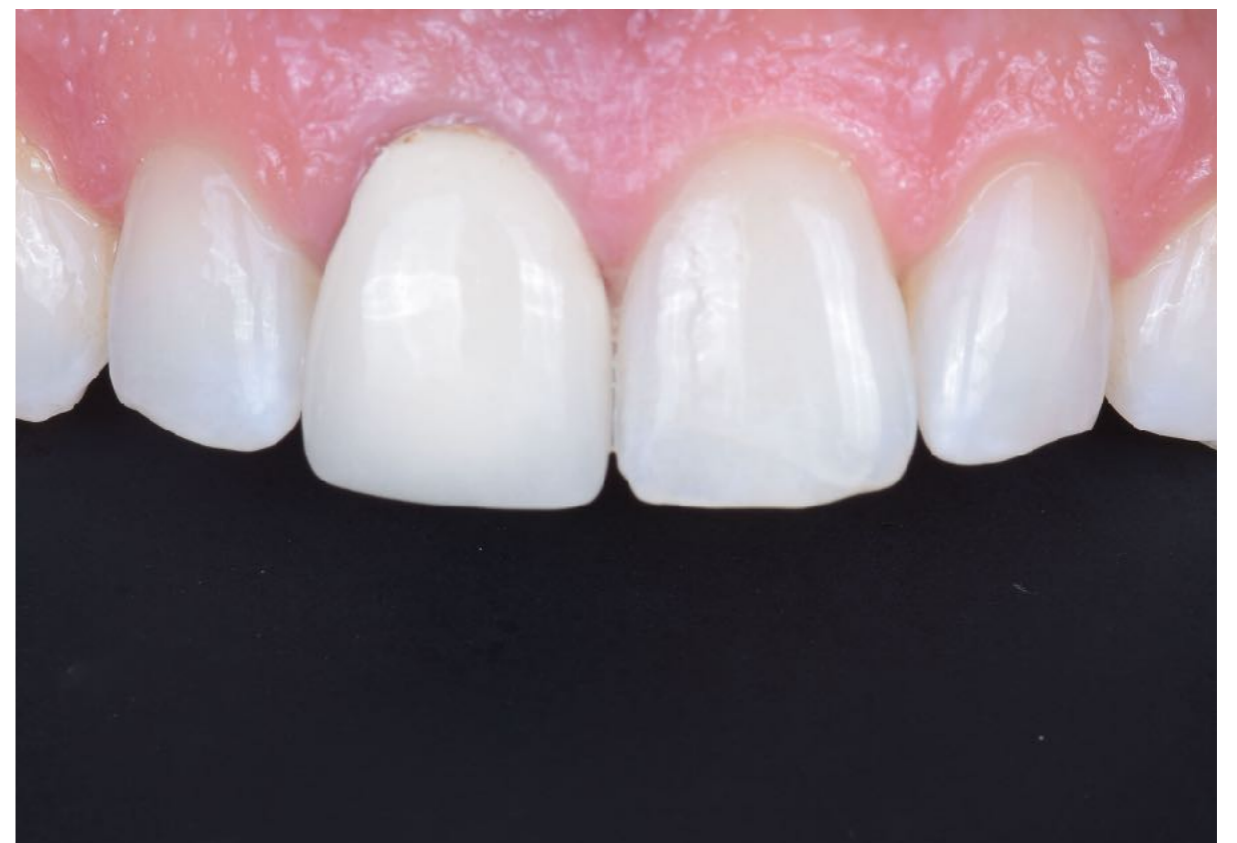SINGLE CENTRAL INCISOR

- The restoration of a single central incisor is challenging since it is the largest, most visible, most centrally-located, and most important anterior tooth in the esthetic zone
- A perfect match vs. the adjacent central must be achieved for perfect aesthetics

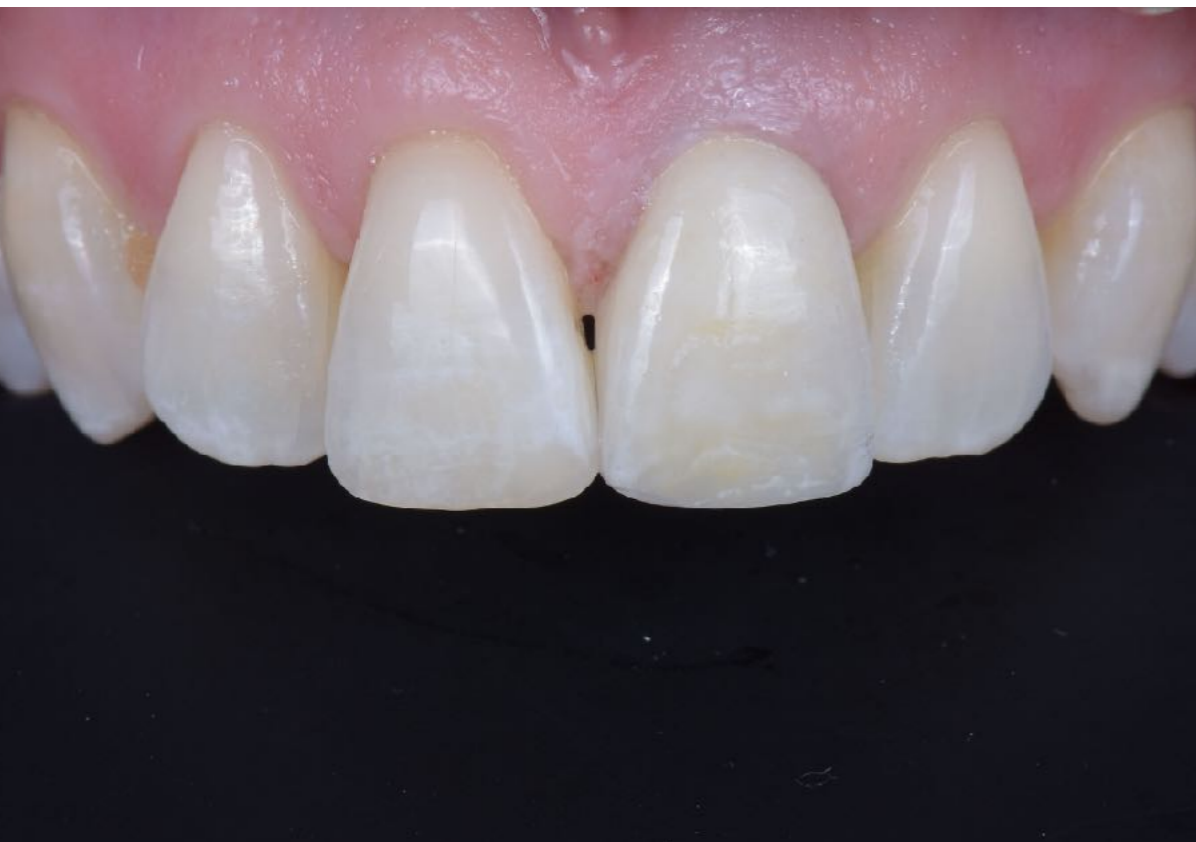



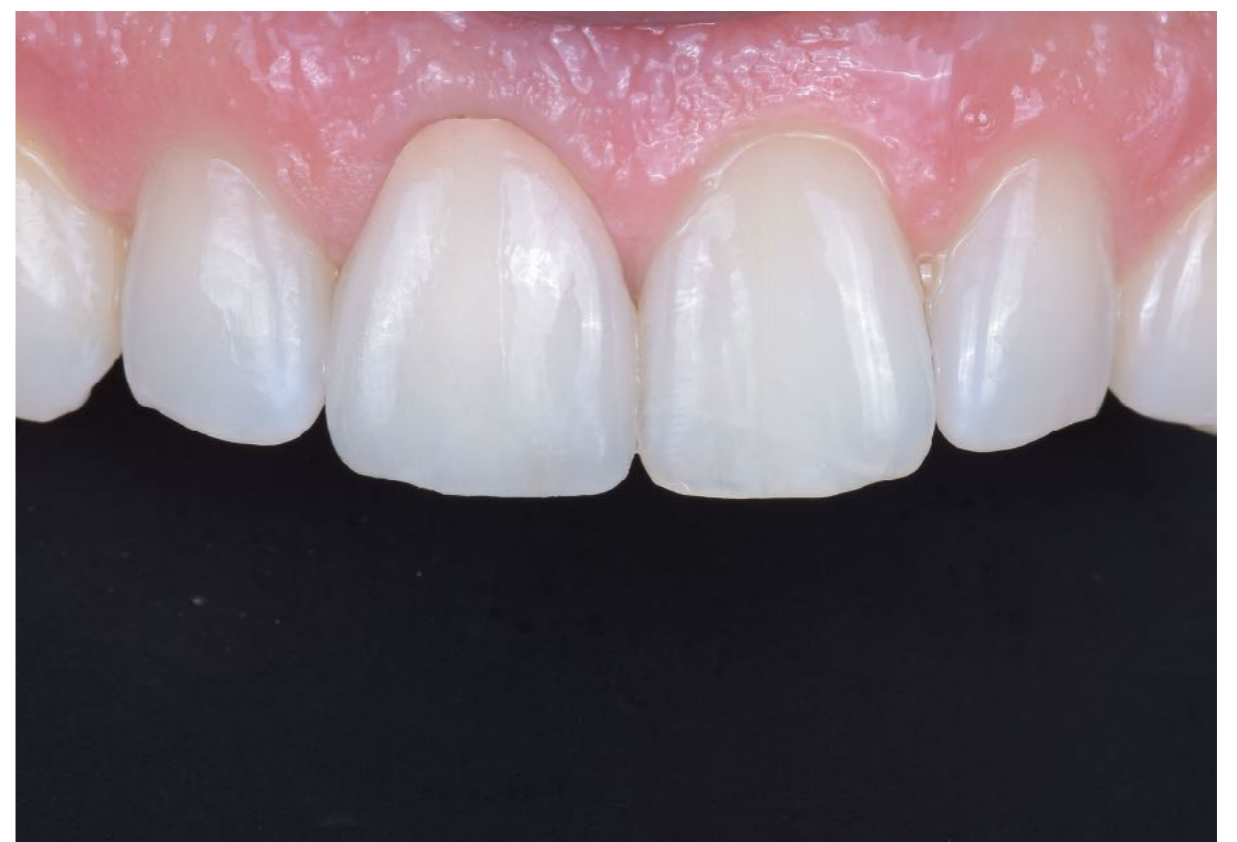Before



After



Before

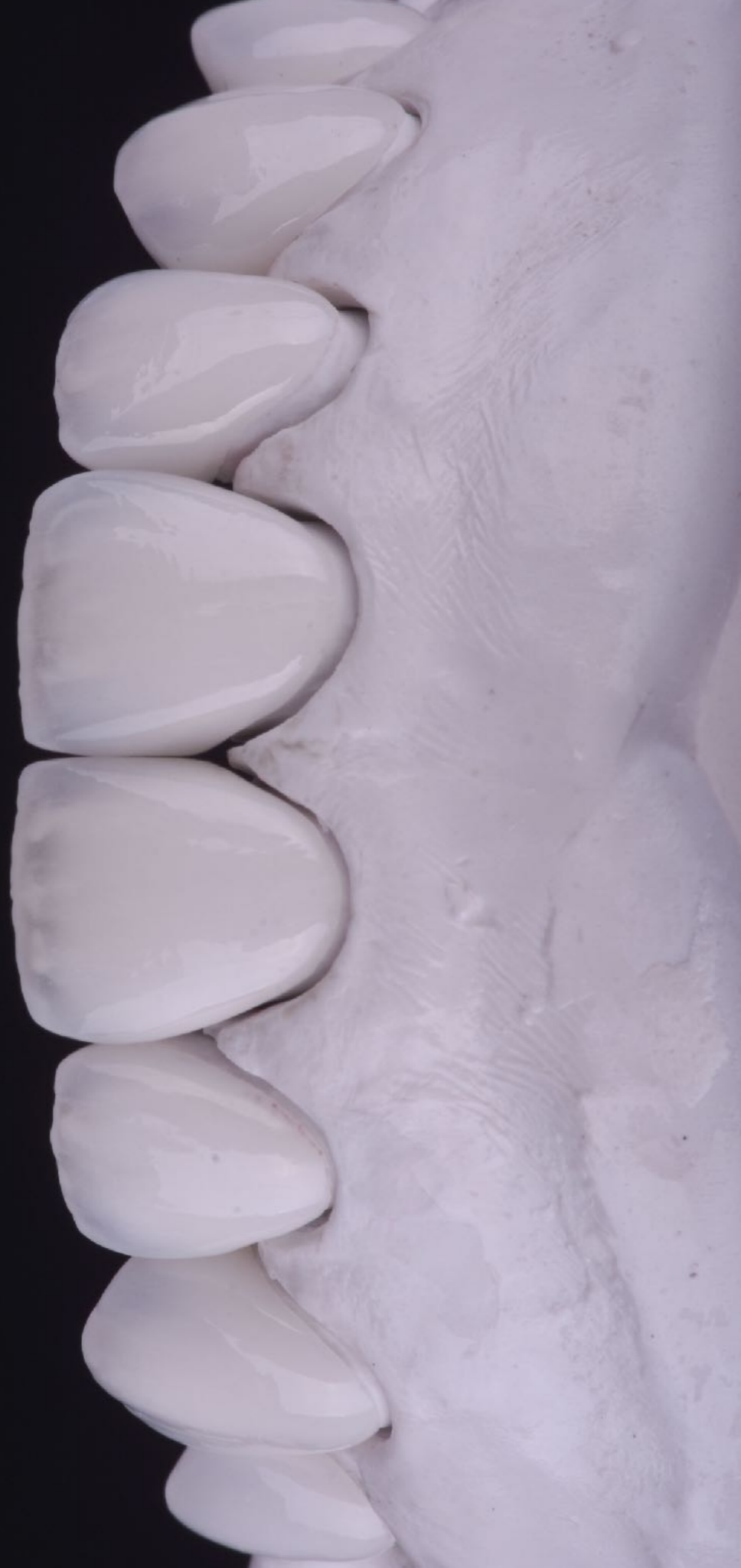

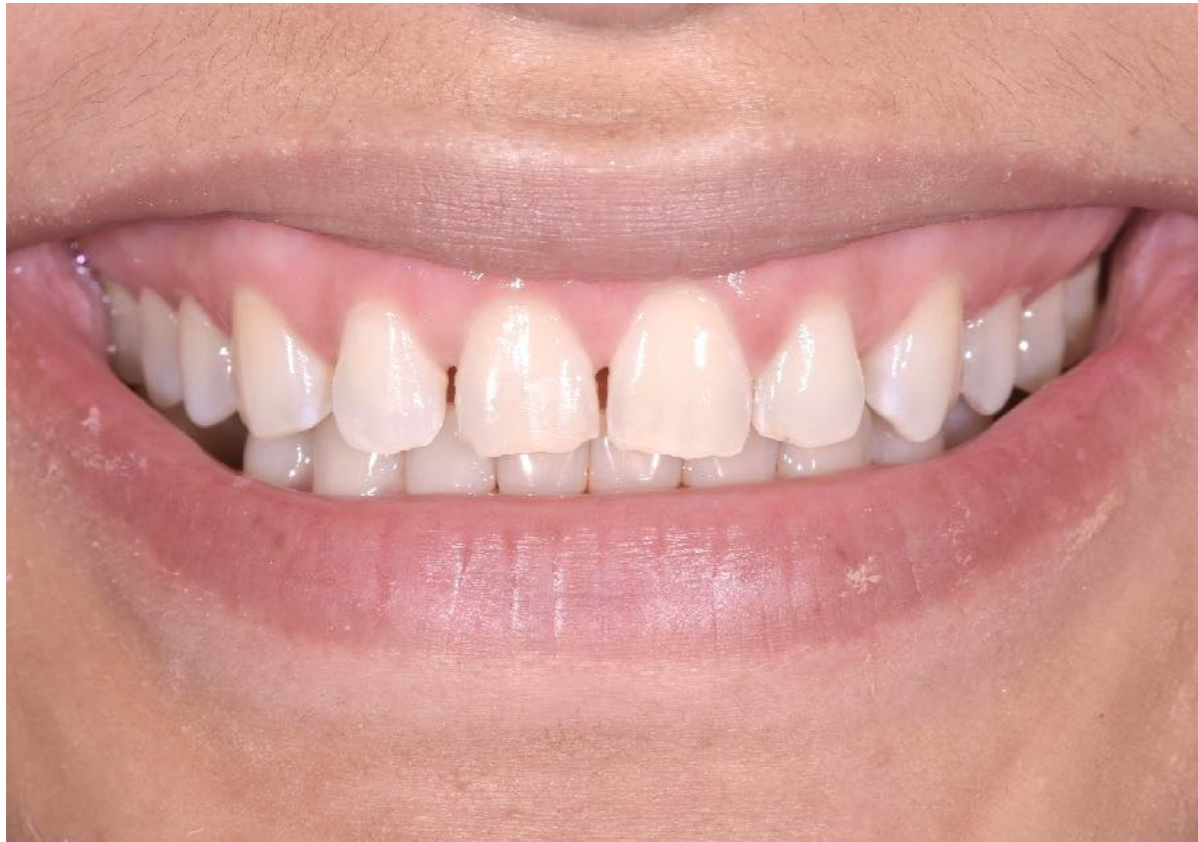After

Where aesthetics meets art...

PORCELAIN VENEERS

- Porcelain veneers can transform the smile and enhance the overall appearance. They can correct a variety of dental imperfections such as stains, chips, gaps, and misalignment.
- Our porcelain veneers are made from high-quality materials that mimic the natural look of teeth and are fabricated by master ceramists.

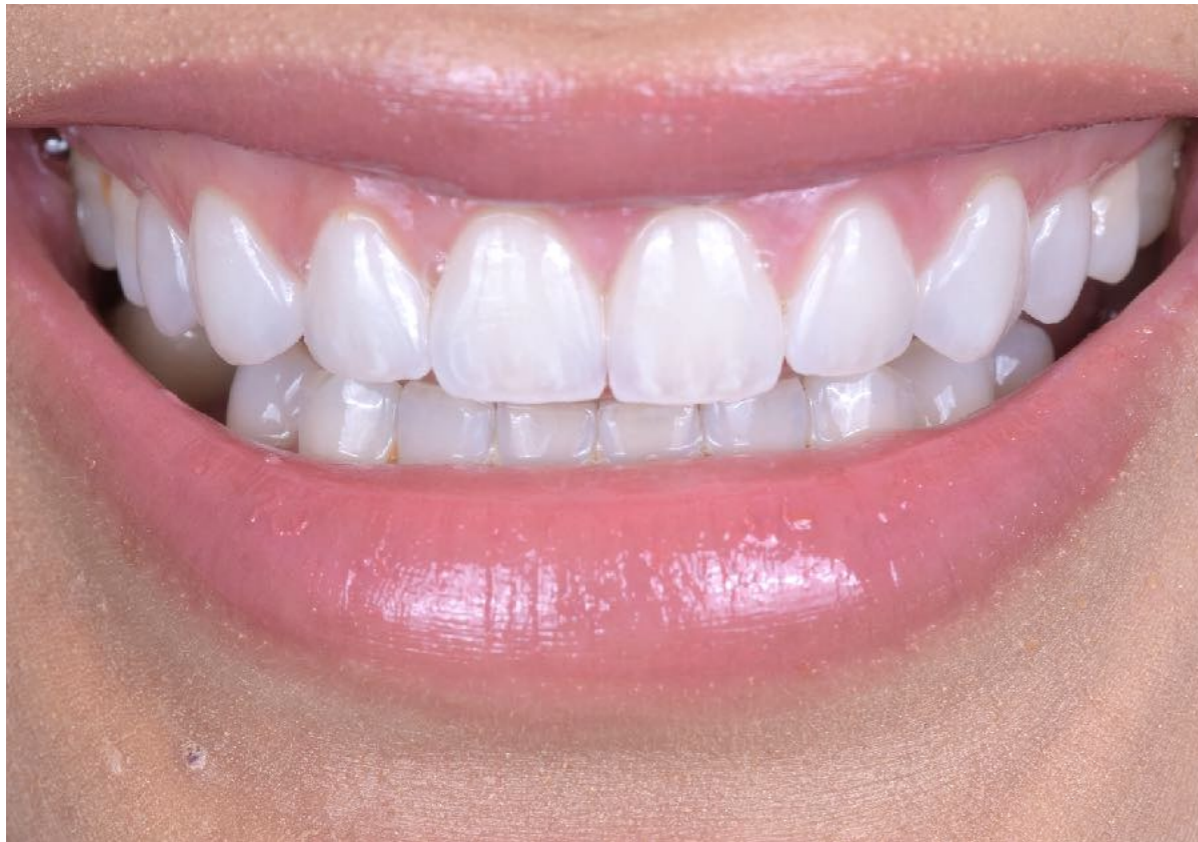


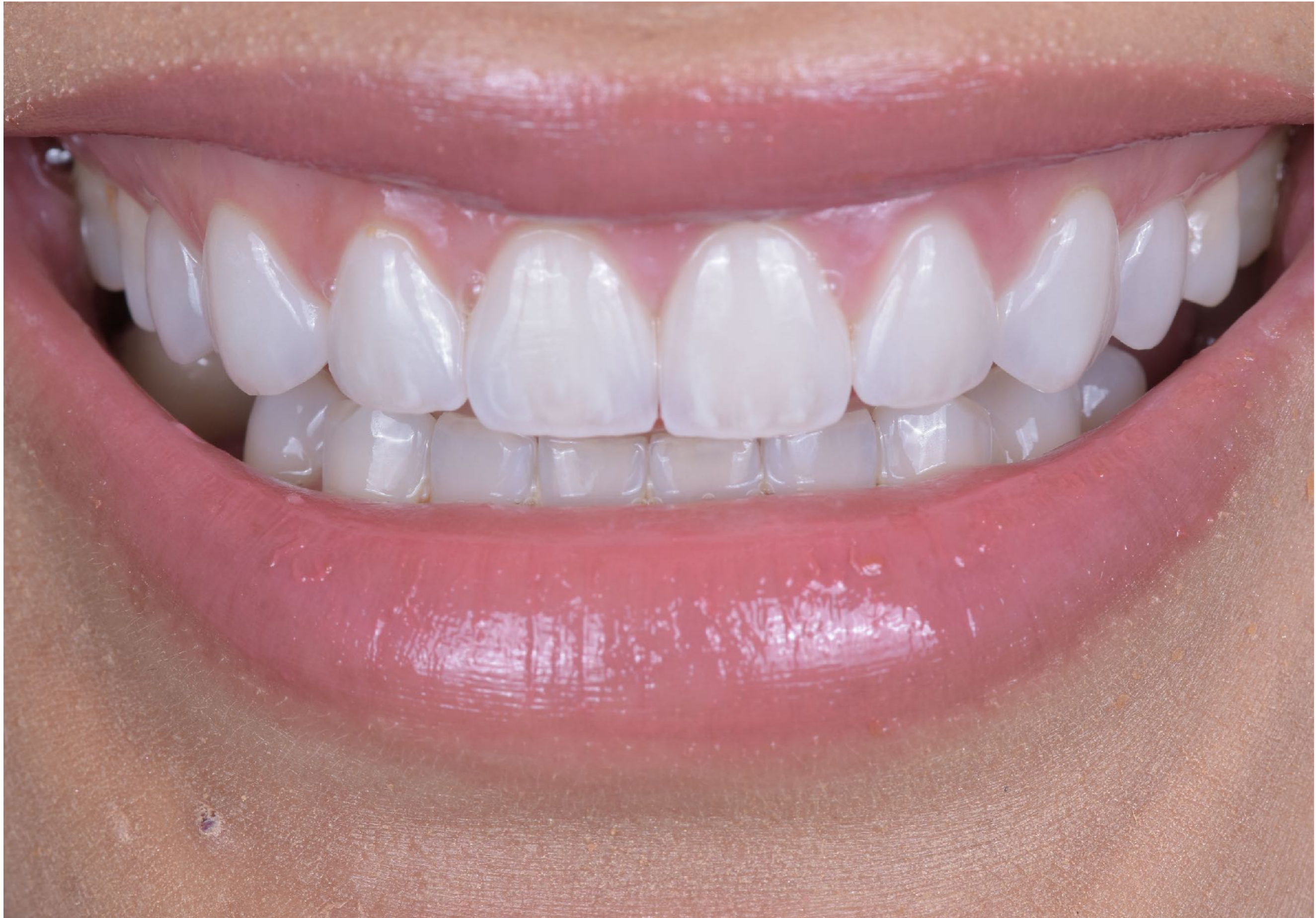
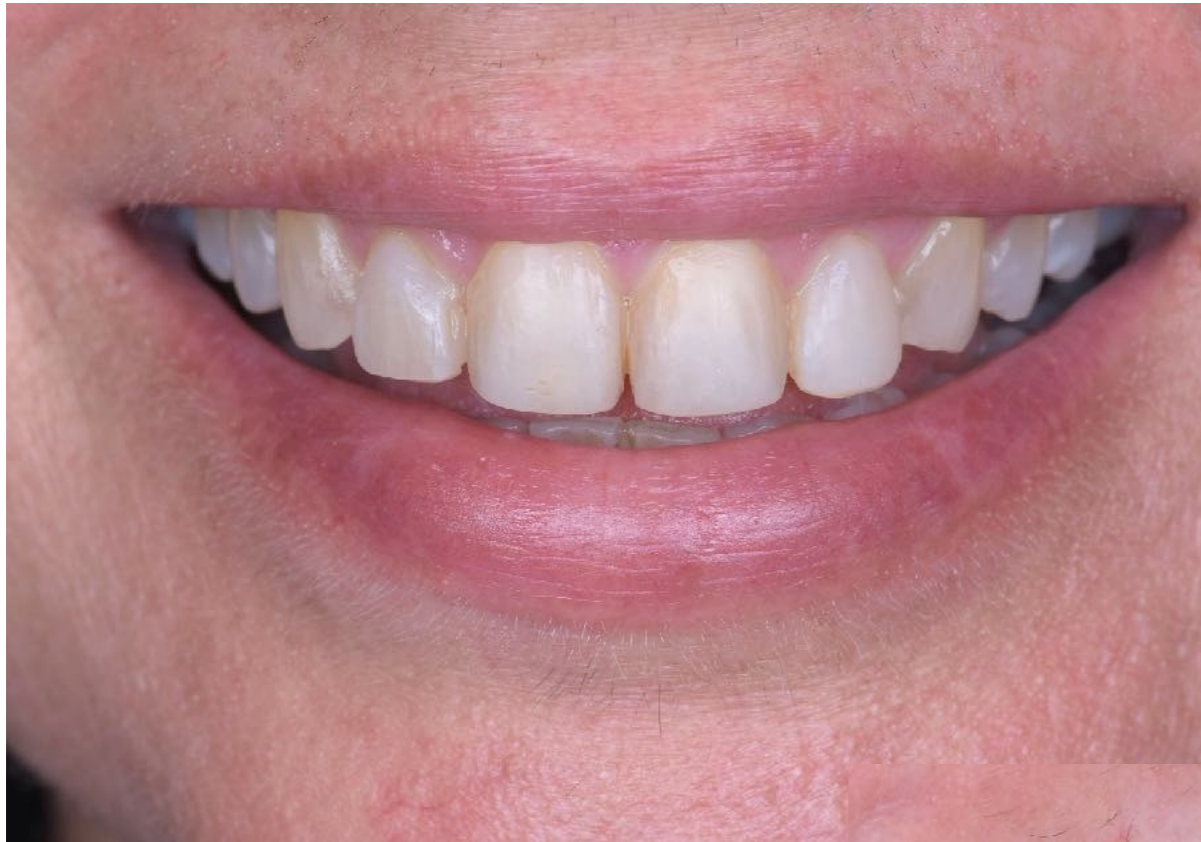Improving the smile with 8 veneers

The patient sought a smile improvement as she wanted to eliminate the gaps and improve the shape of her teeth.

8 porcelain veneers were fabricated to close the gaps, change the shape of the teeth, the size and the colour.



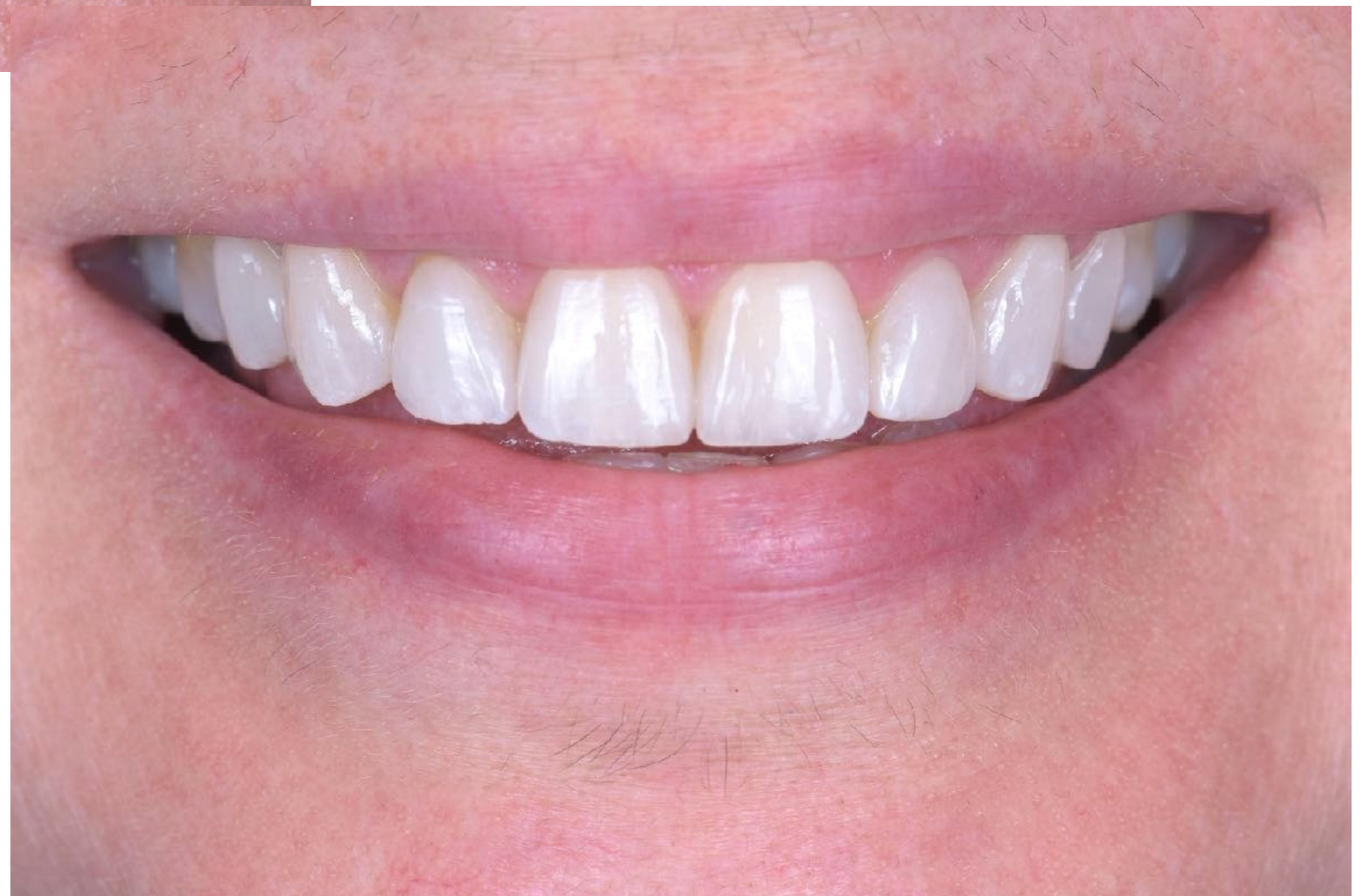


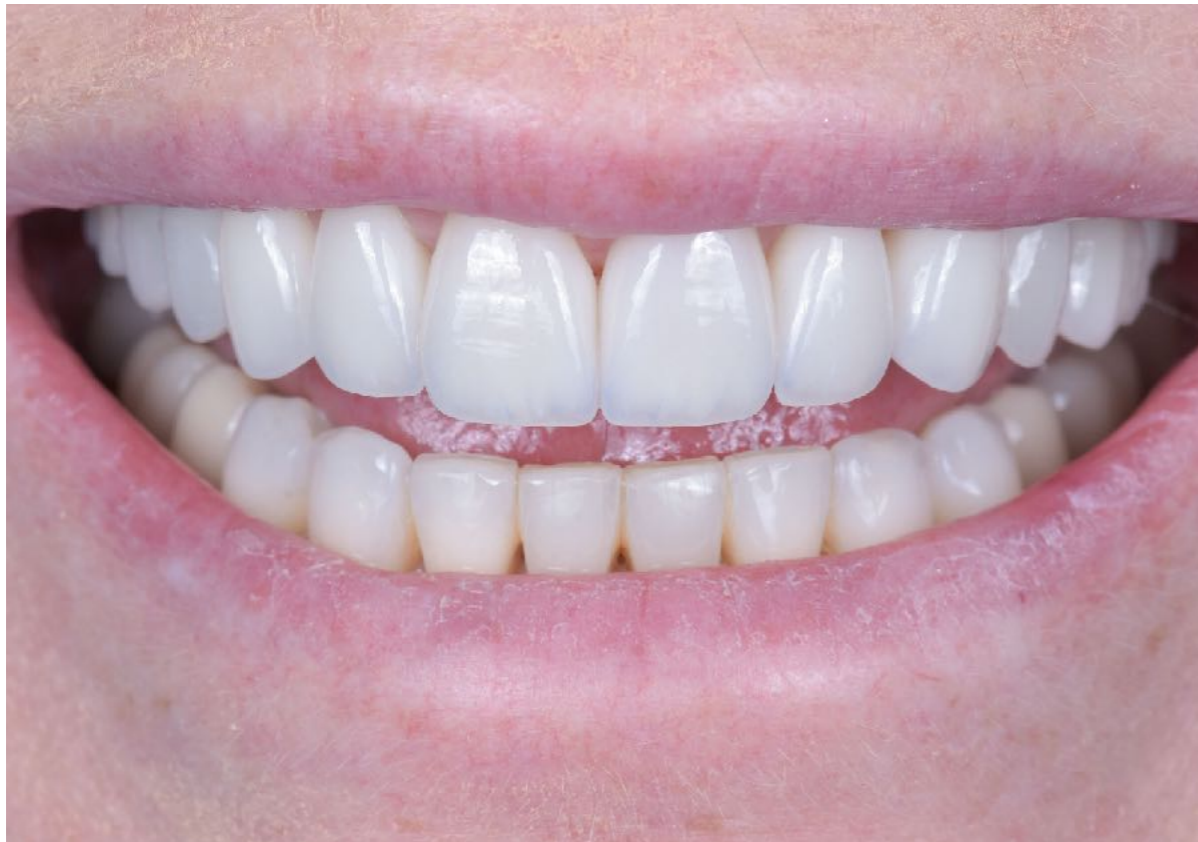
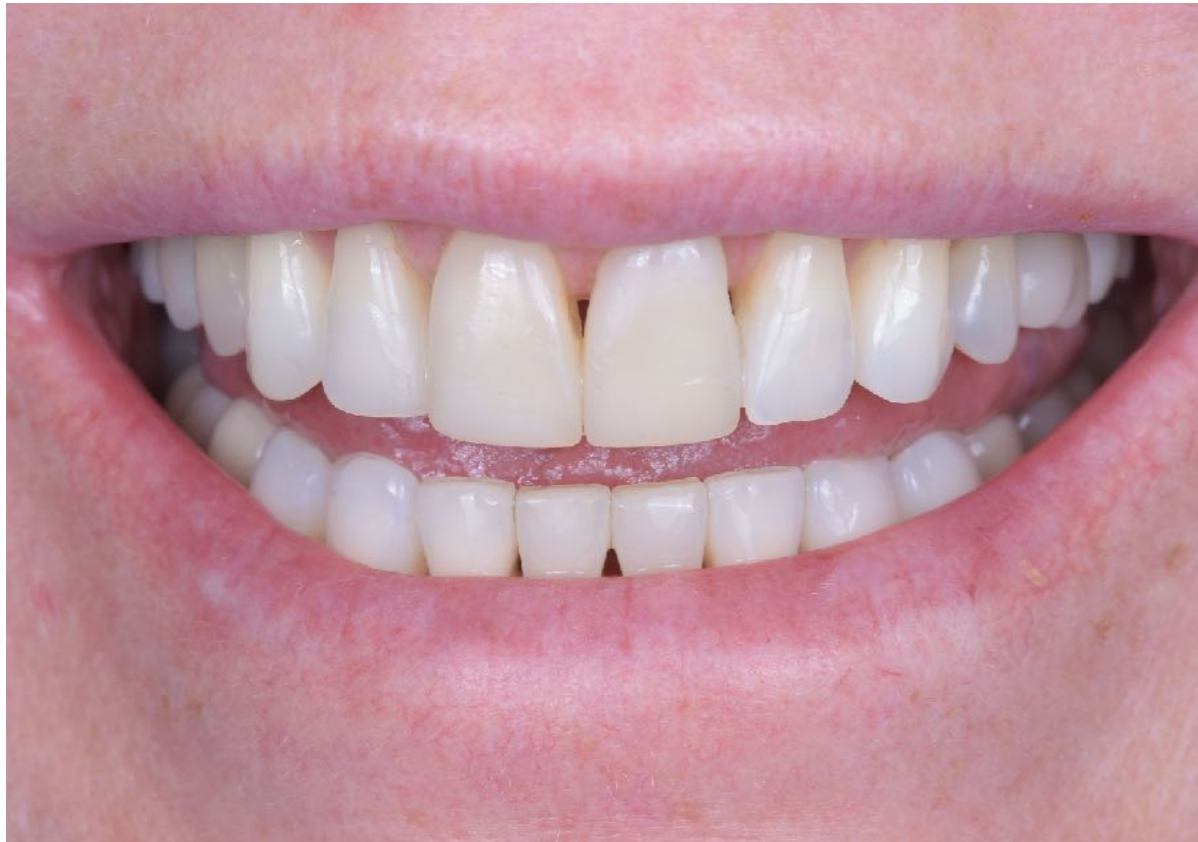8 porcelain veneers

The patient sought a brighter smile due to the shape and colour of her teeth.

Porcelain veneers were used.

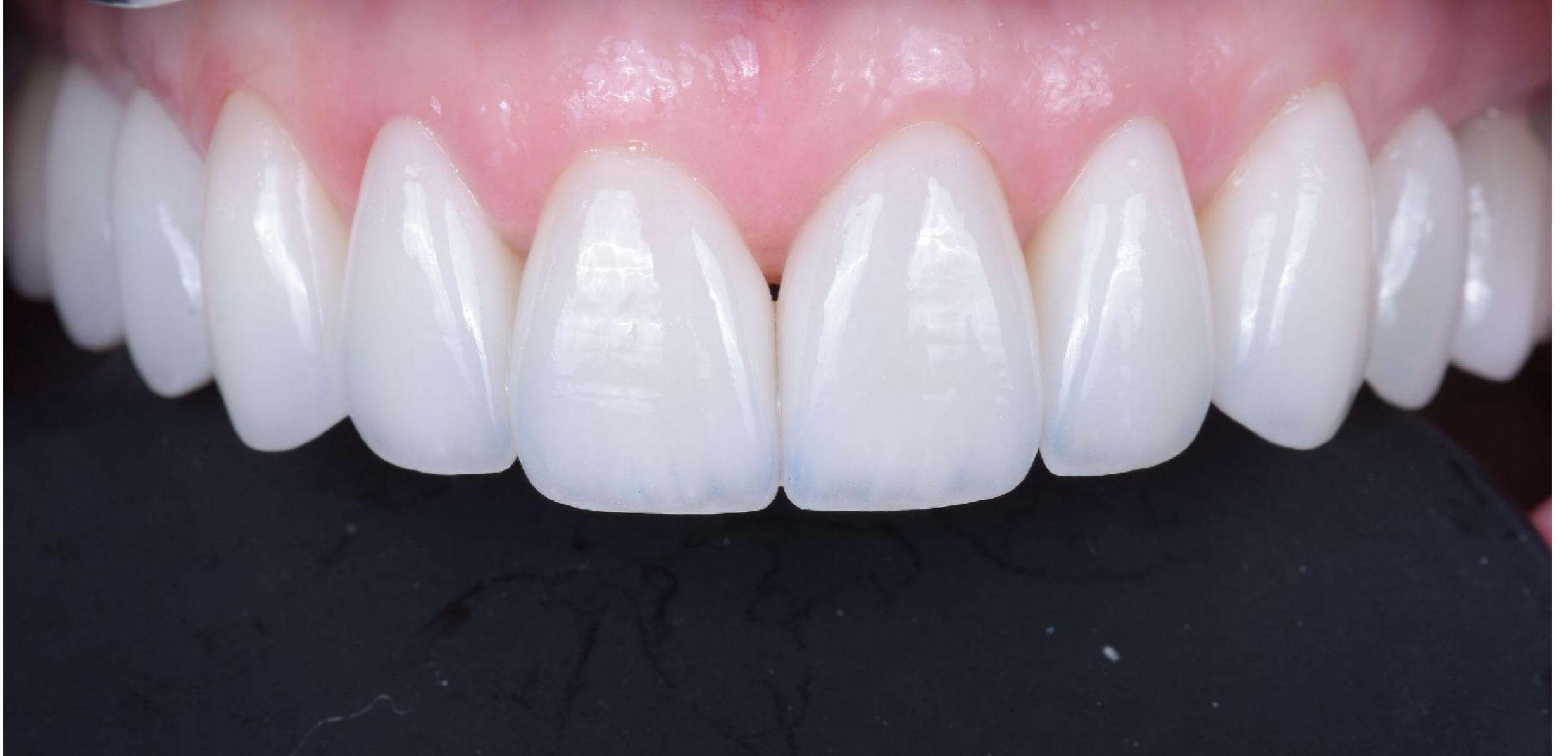
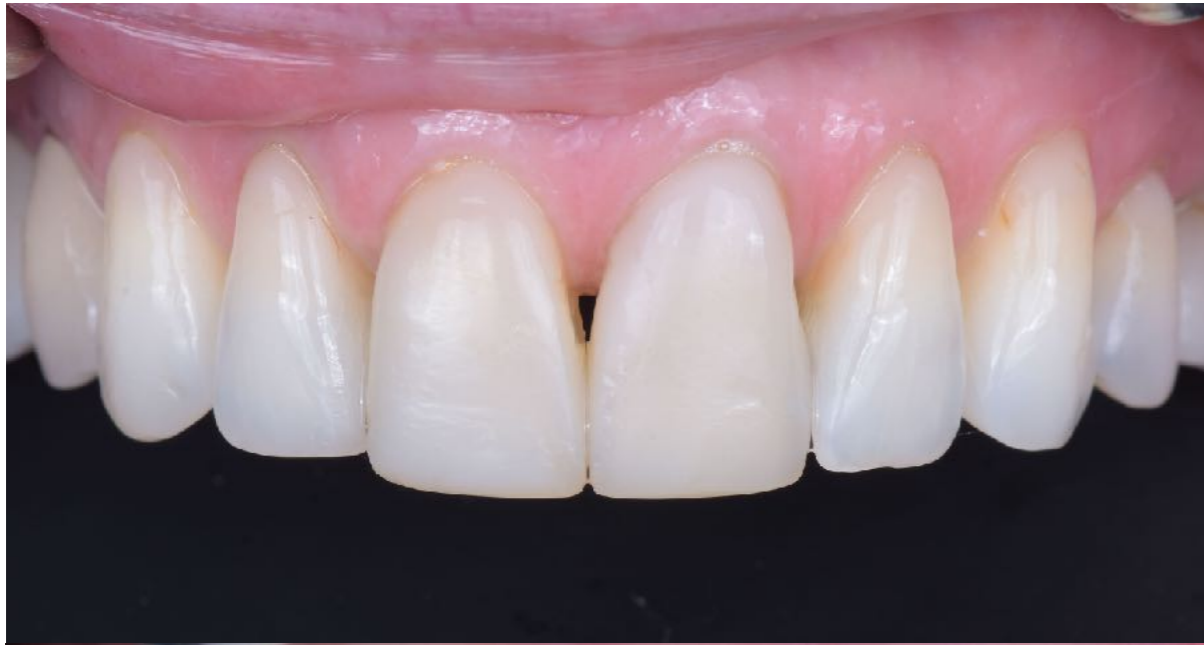


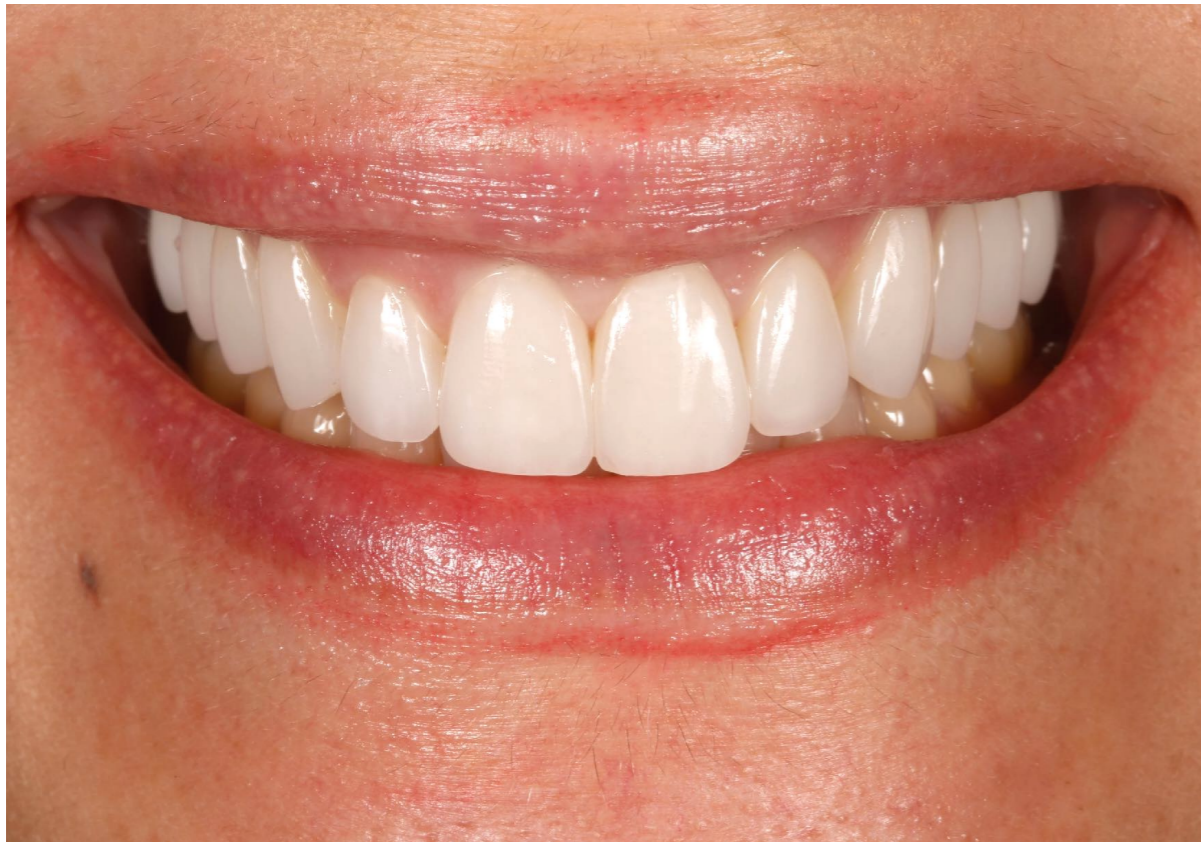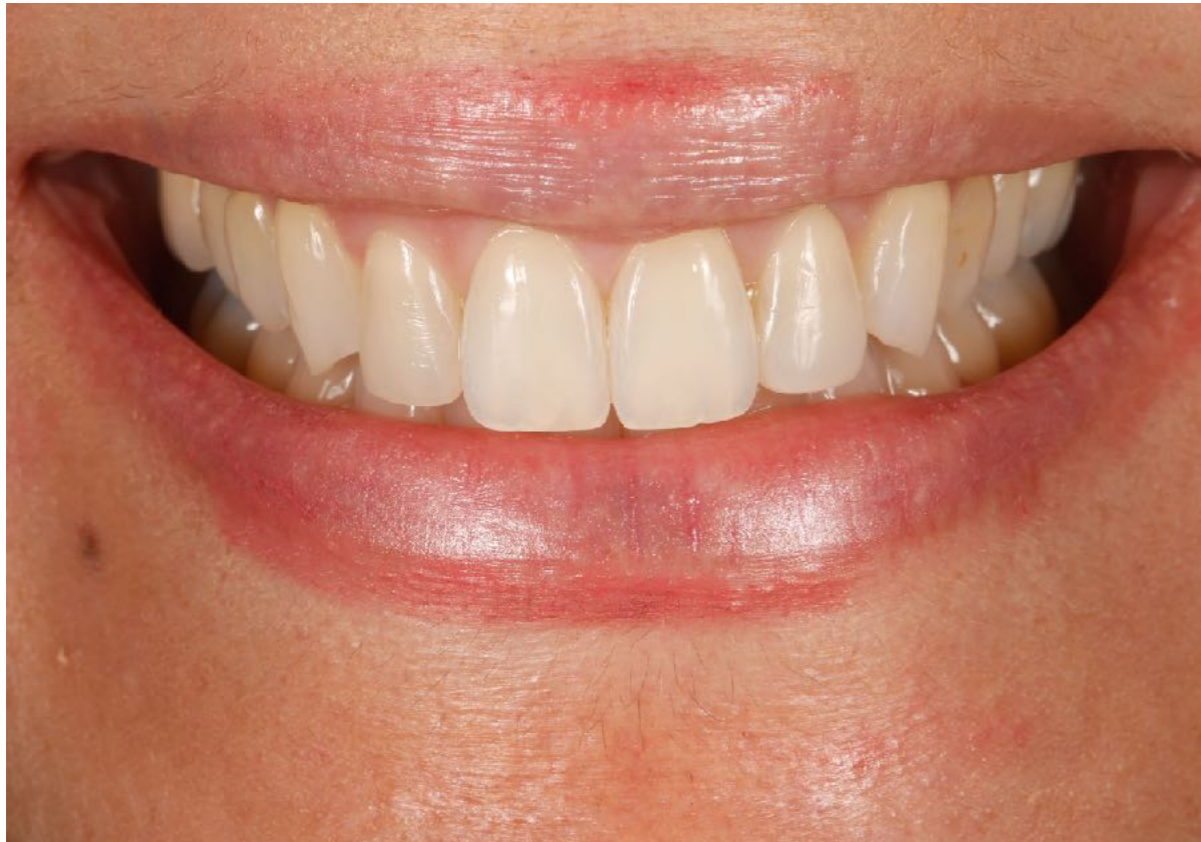A smile transformation with 10 veneers

This lady wanted to brighten her smile and take advantage of technically advanced materials.

10 Porcelain veneers were used, customized, to improve the shape, colour, and contour of the teeth.

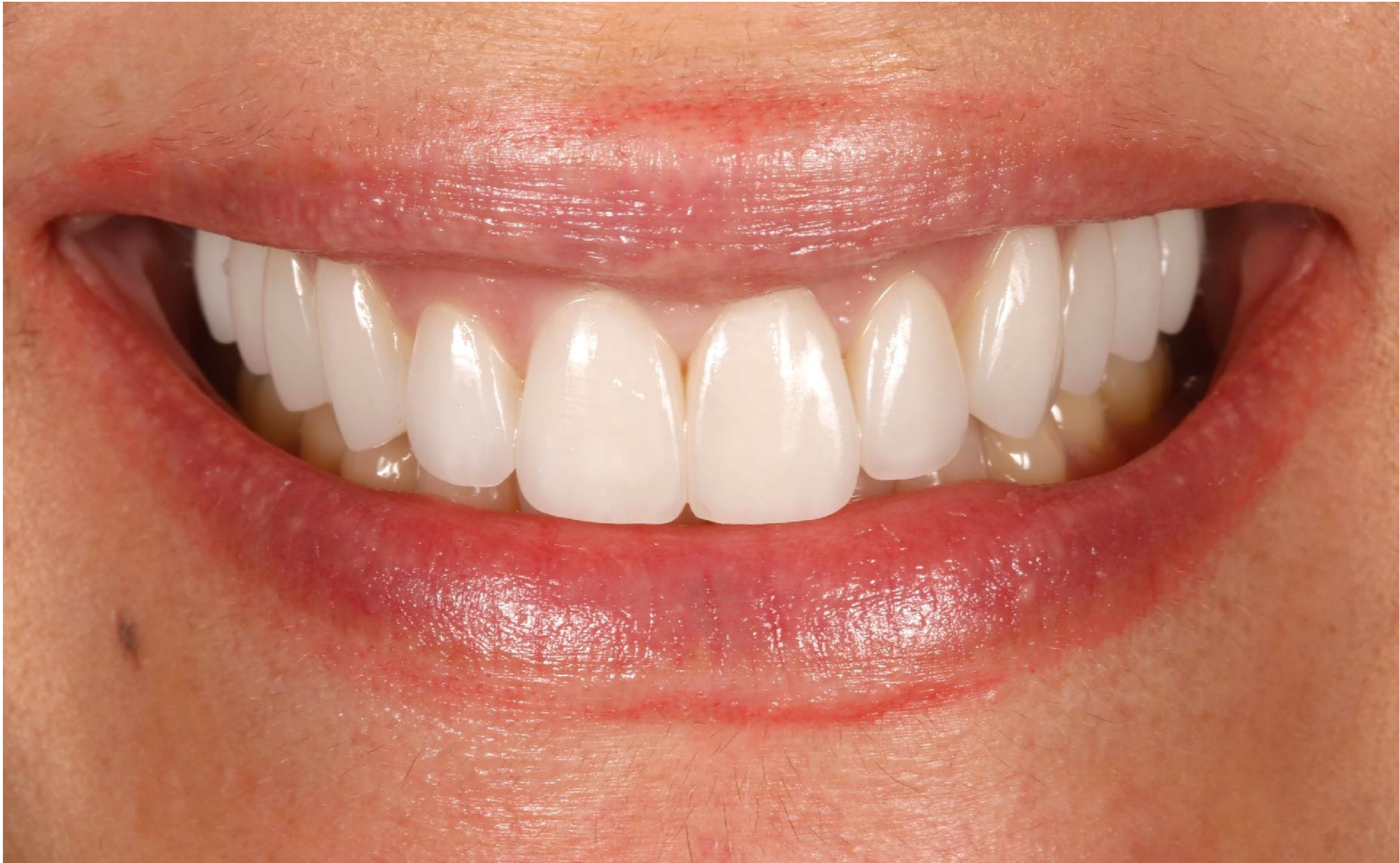



A smile transformation with 12 veneers

This lady wanted to brighten her smile and take advantage of technically advanced materials.

12 Porcelain veneers were used, customized, to improve the shape, colour, and contour of the teeth, but keeping the same "character" of her natural teeth.

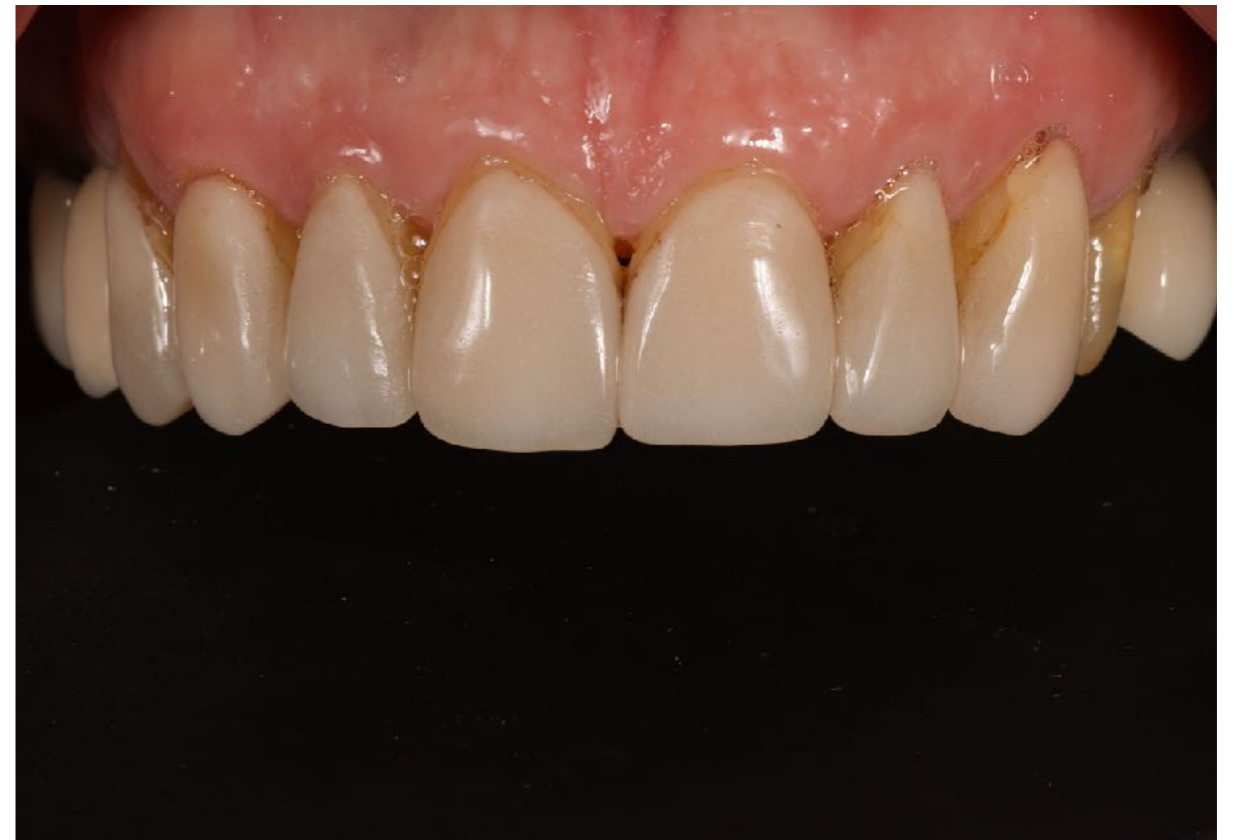
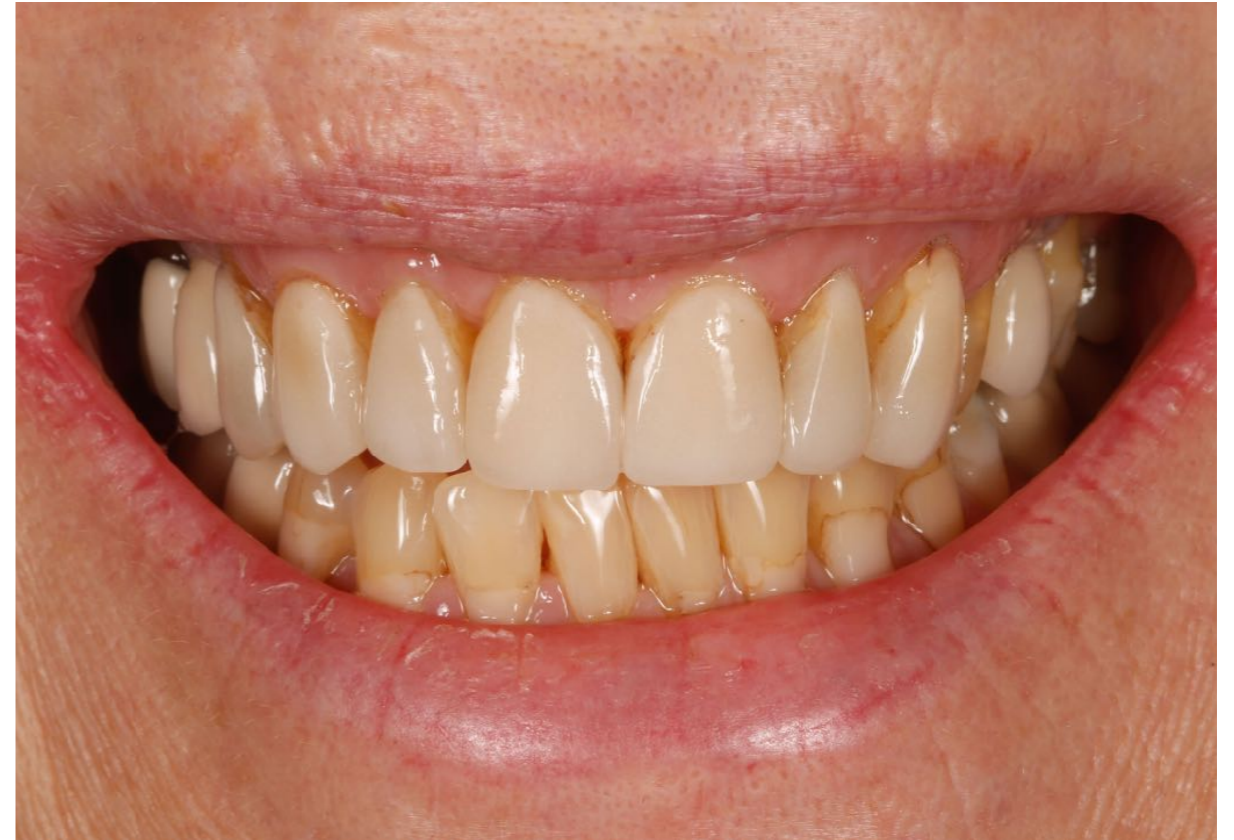
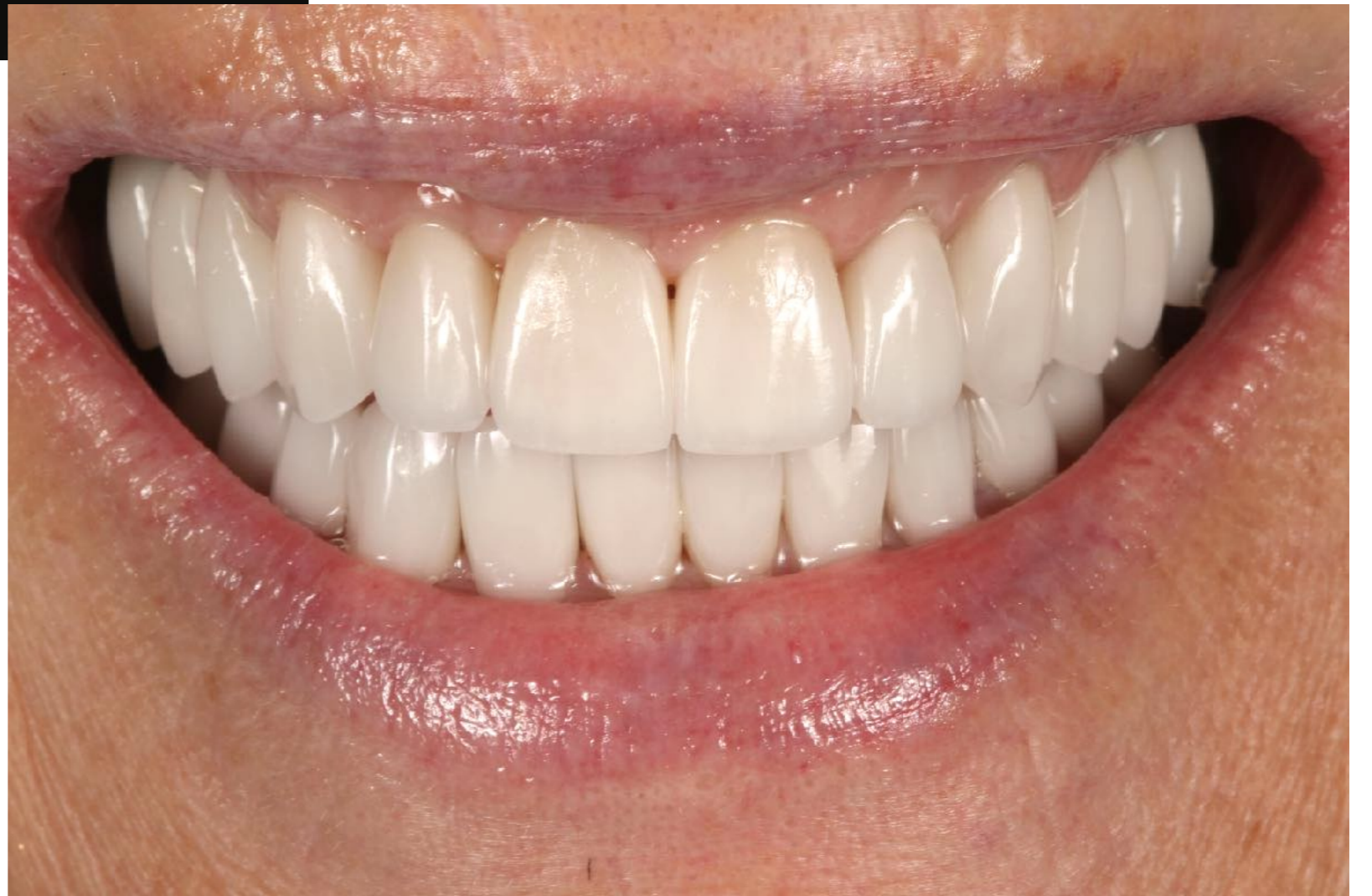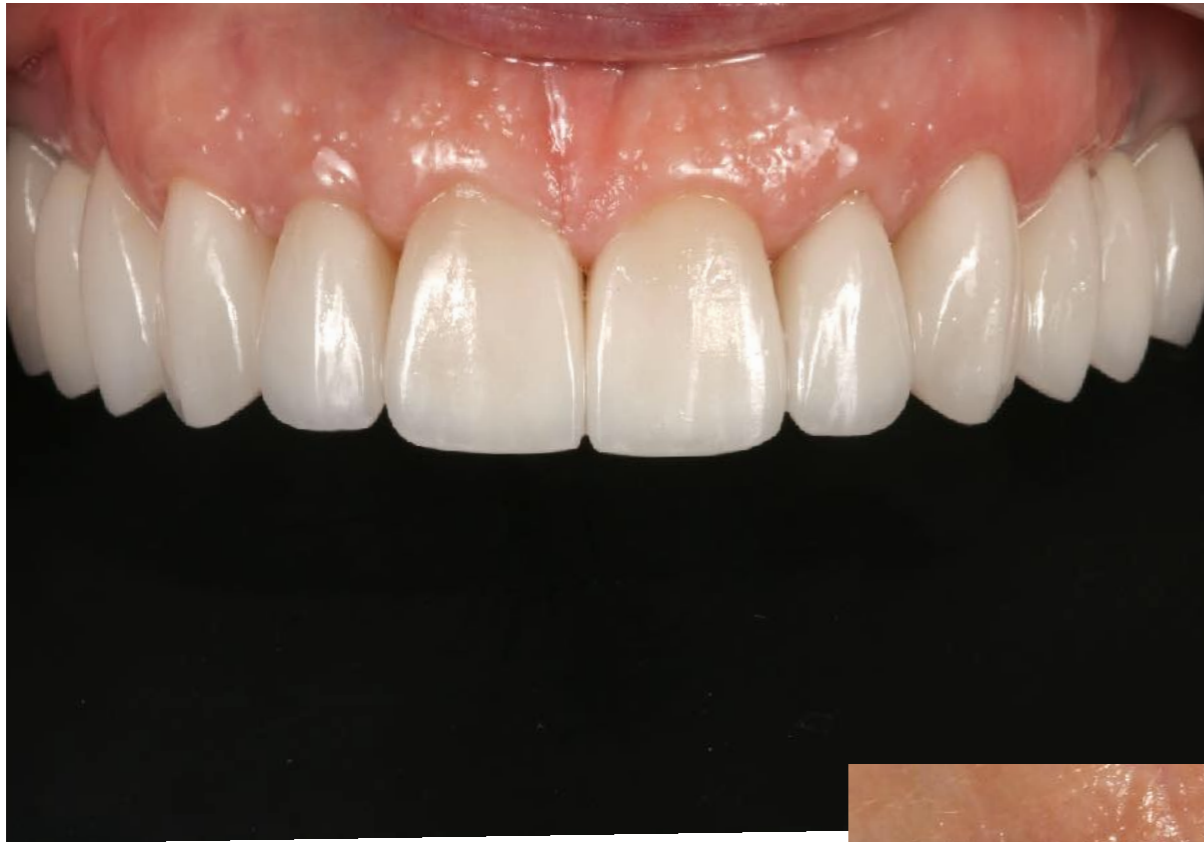Revision #1

This patient had old porcelain veneers in the maxillary arch. Also the rest of the teeth were restored, in multiple occasions, with composite.

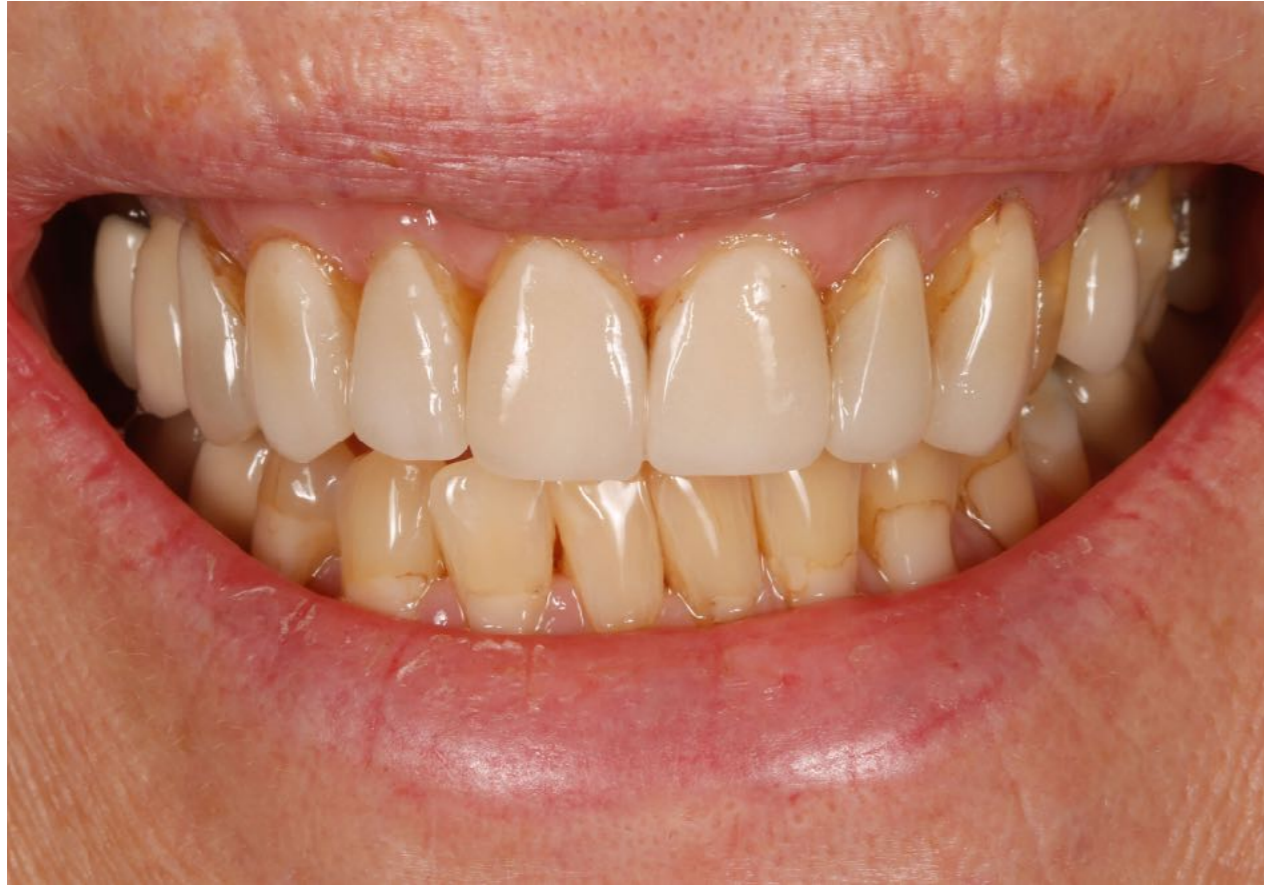Needless to say that she was not happy with her smile.

A comprehensive rehabilitation was completed with new porcelain veneers, and 2 crowns, to rejuvenate and dramatically improve her smile.

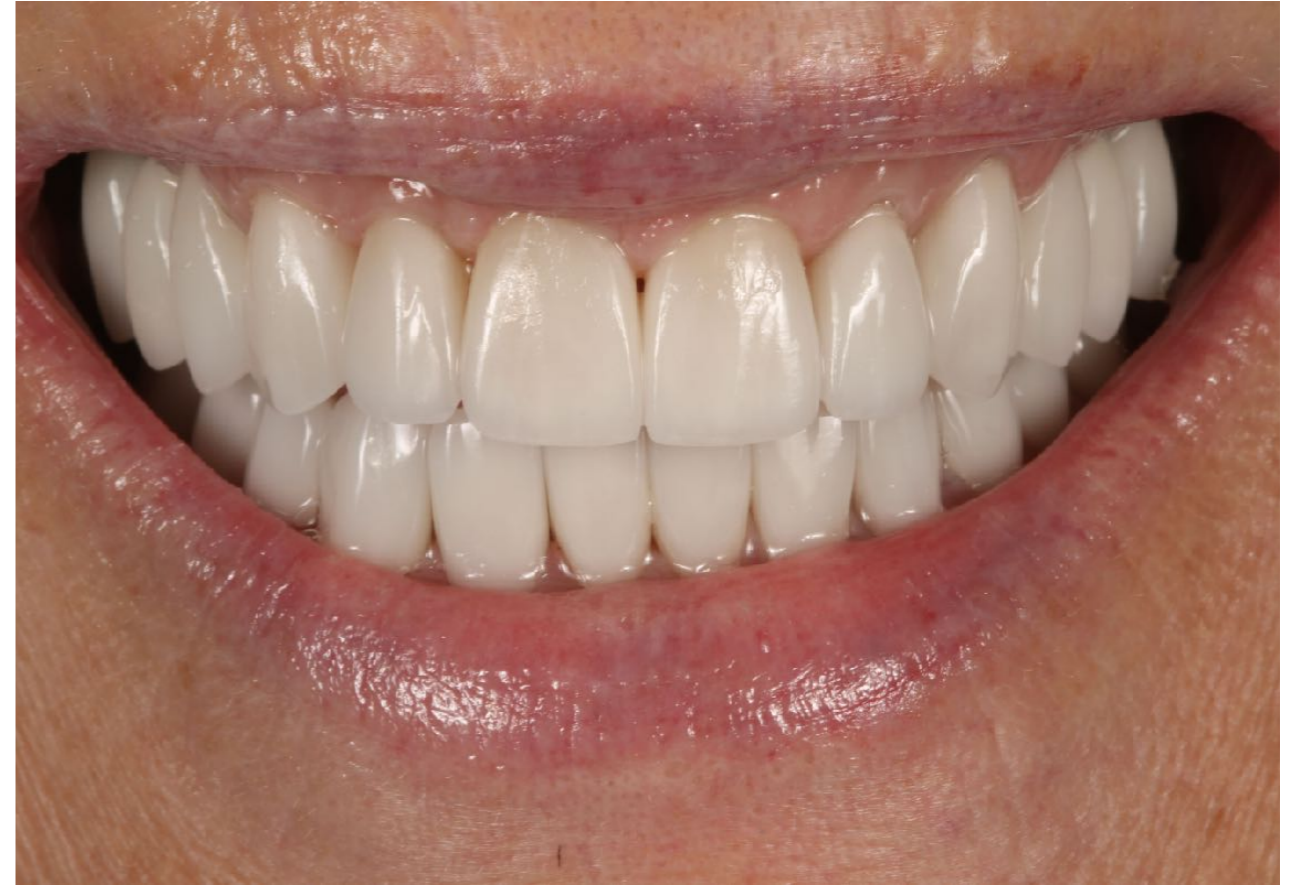



Before

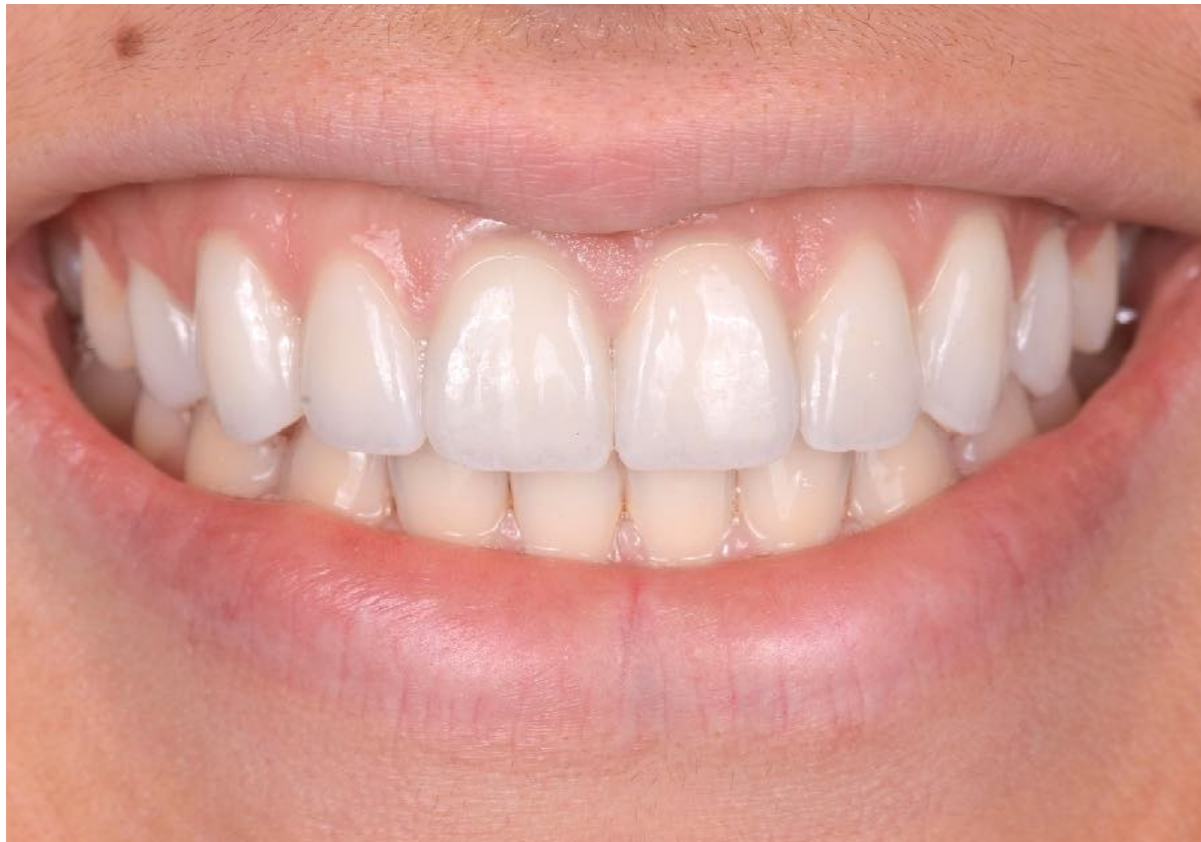
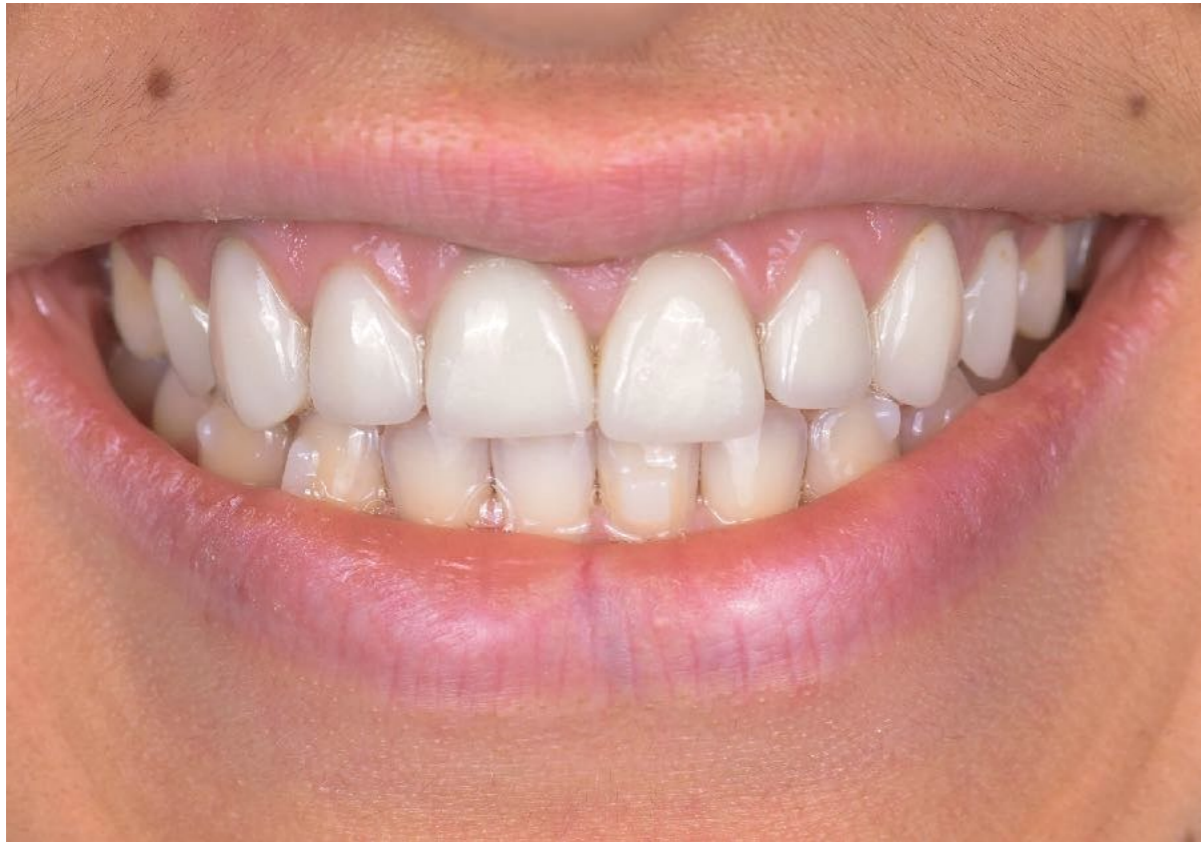
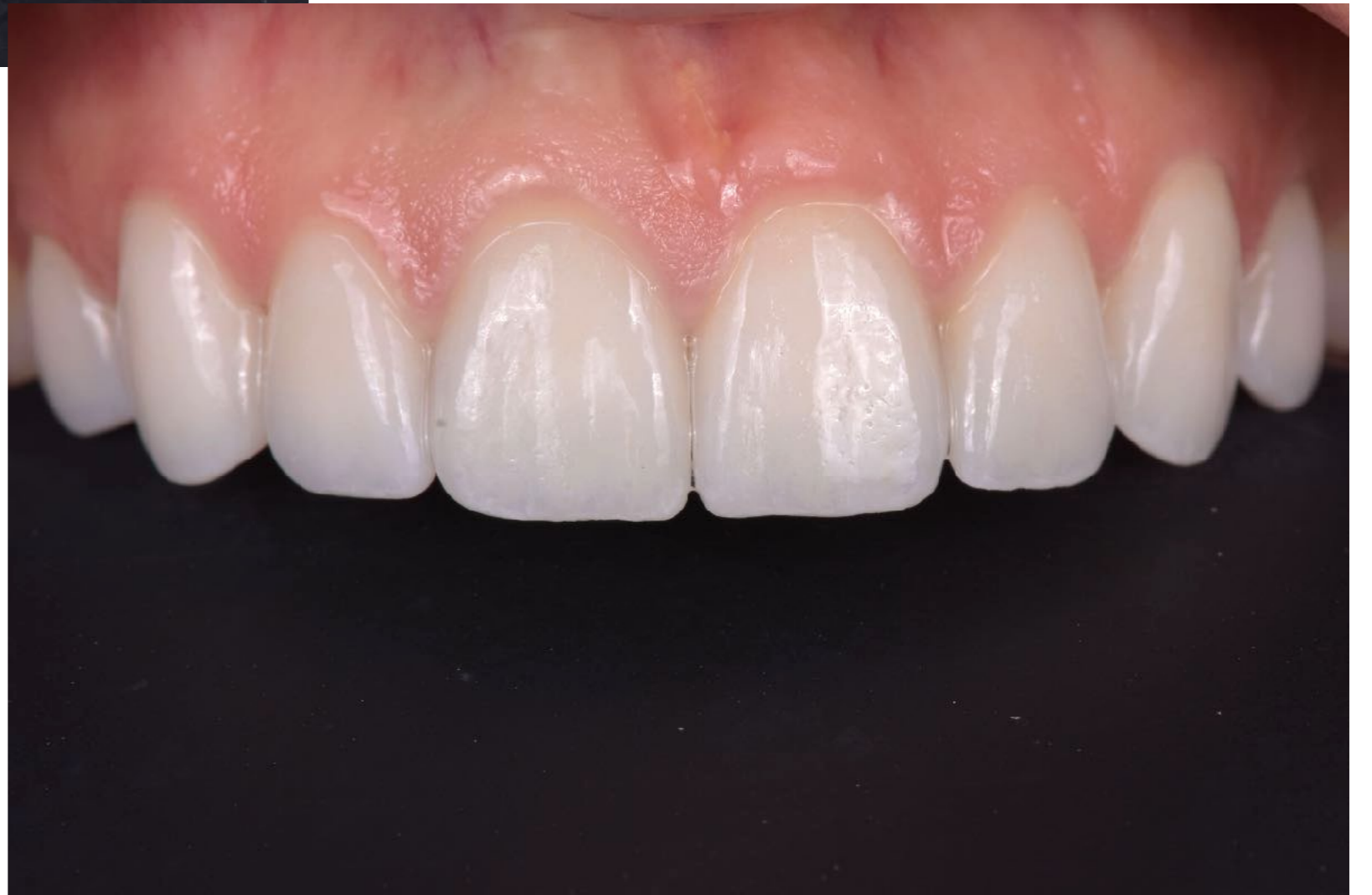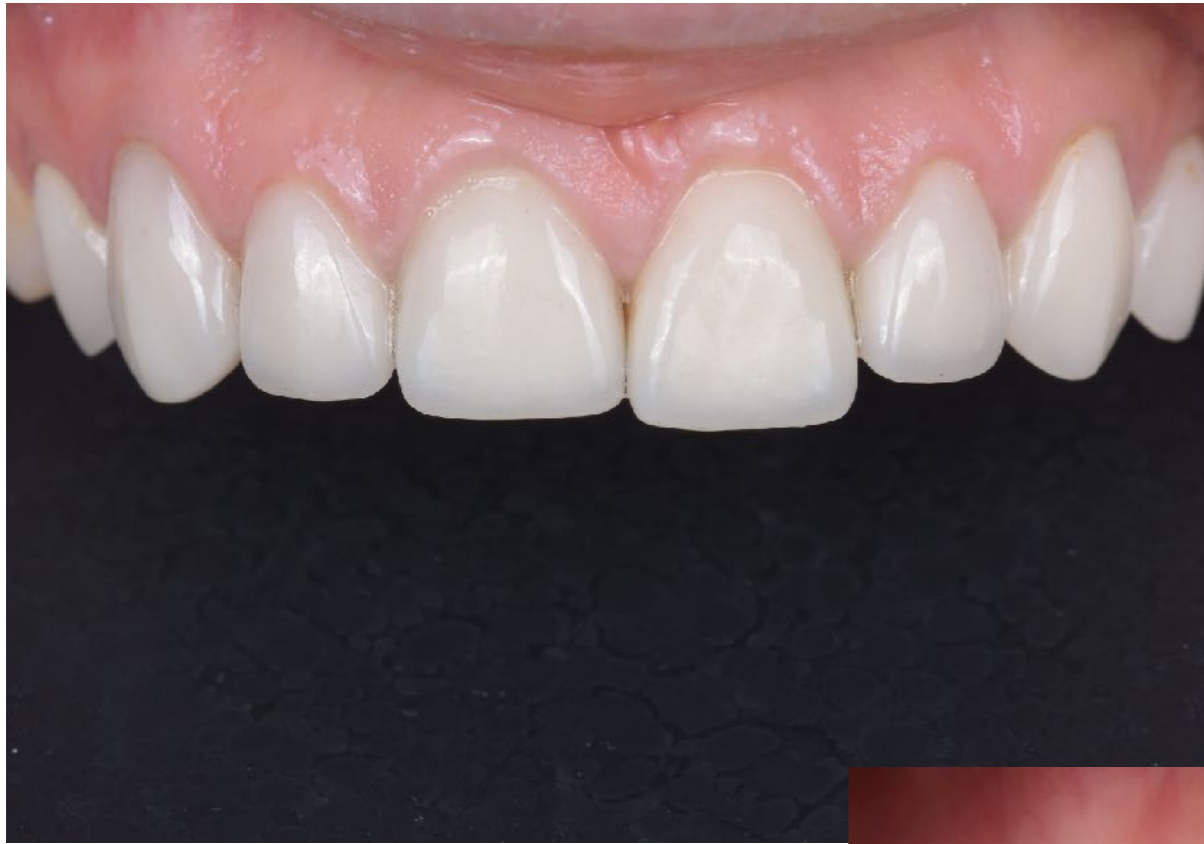After



Revision #2

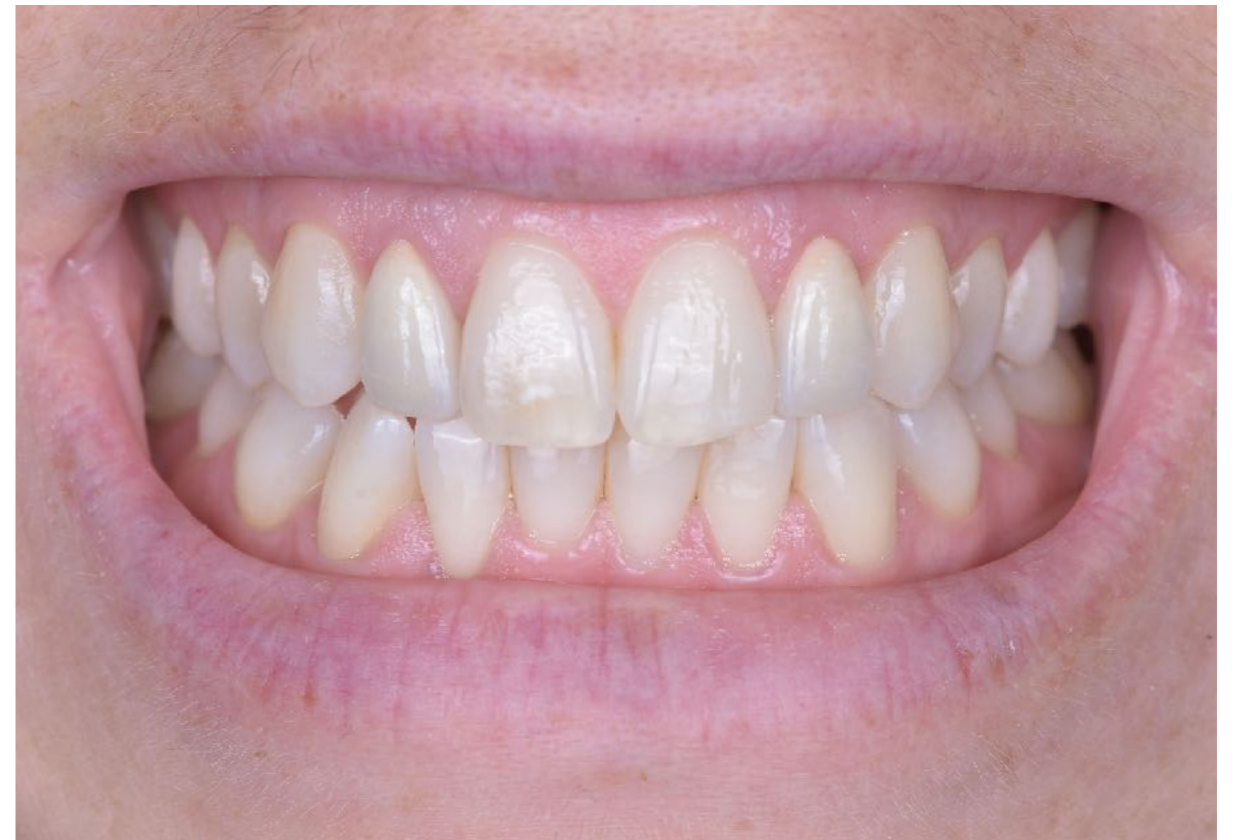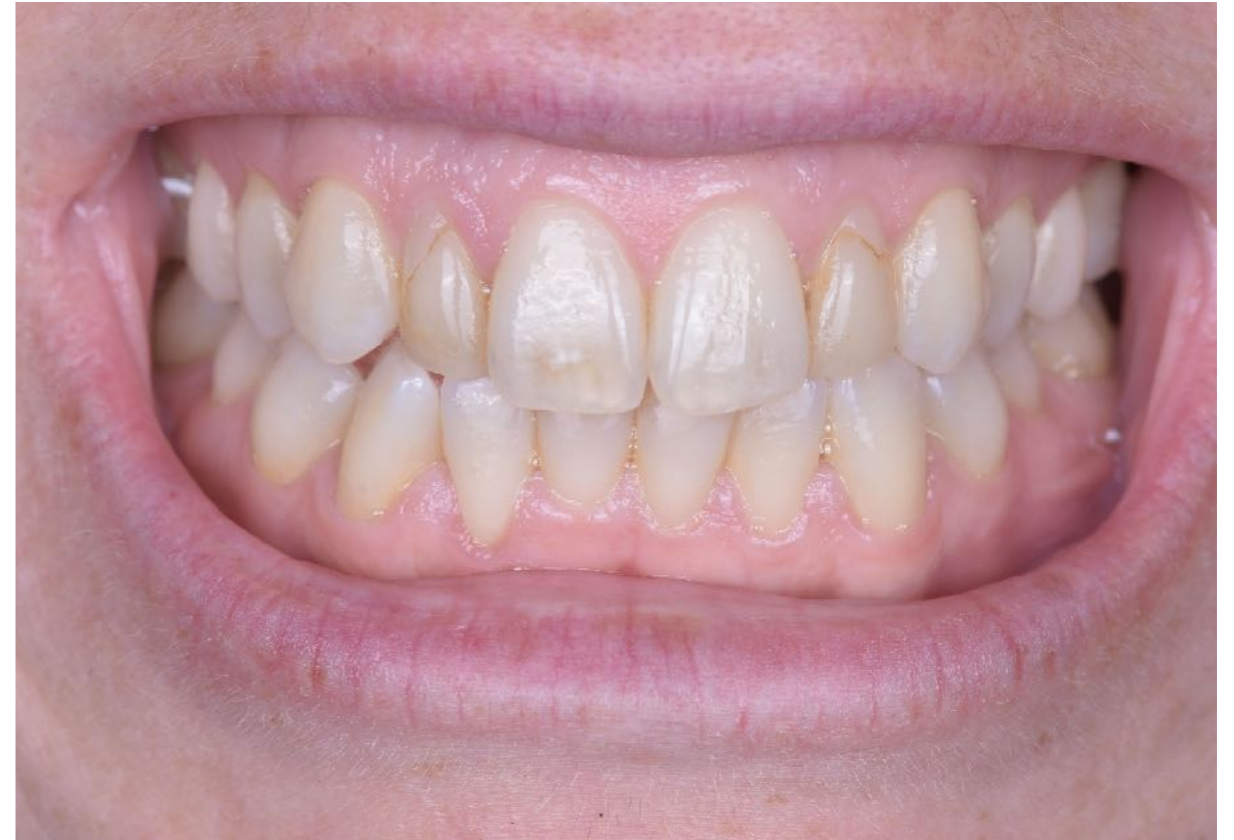Old unaesthetic porcelain veneers replaced by a new set:
better smile and more natural "look"...

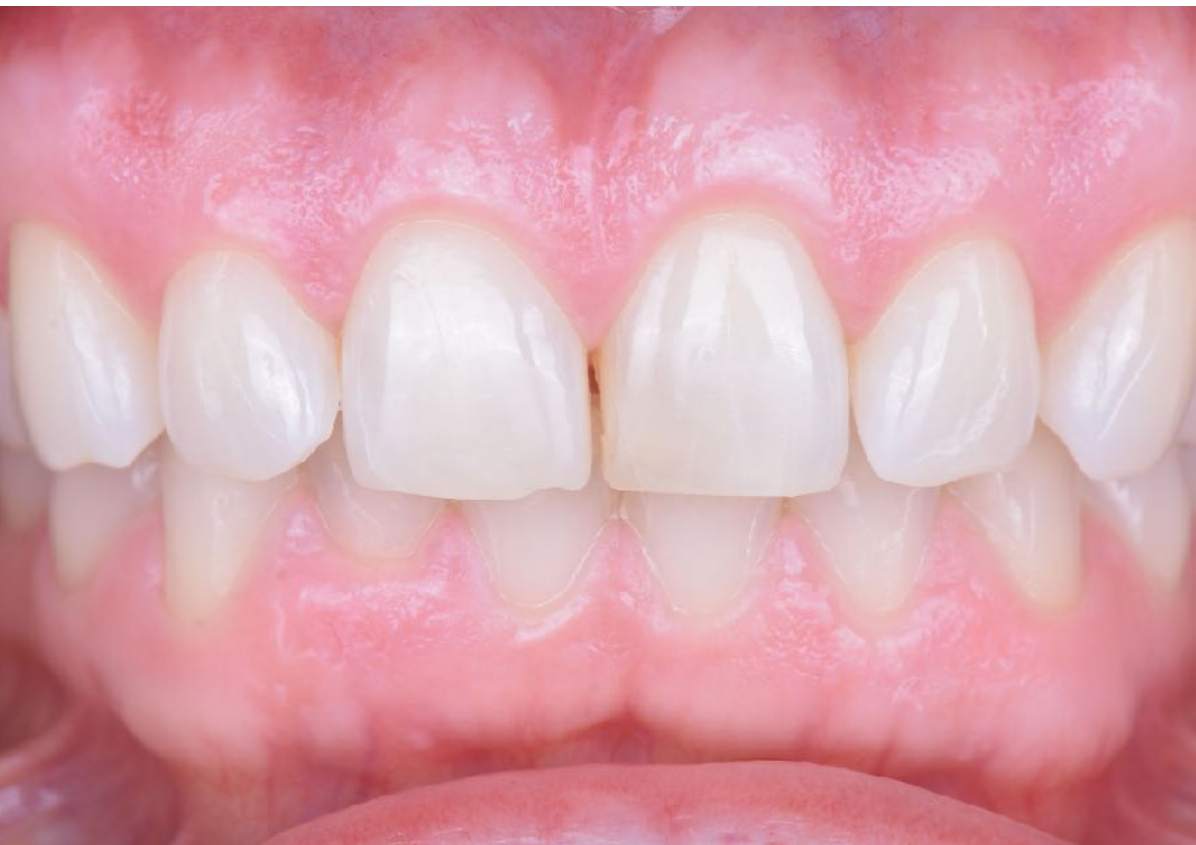



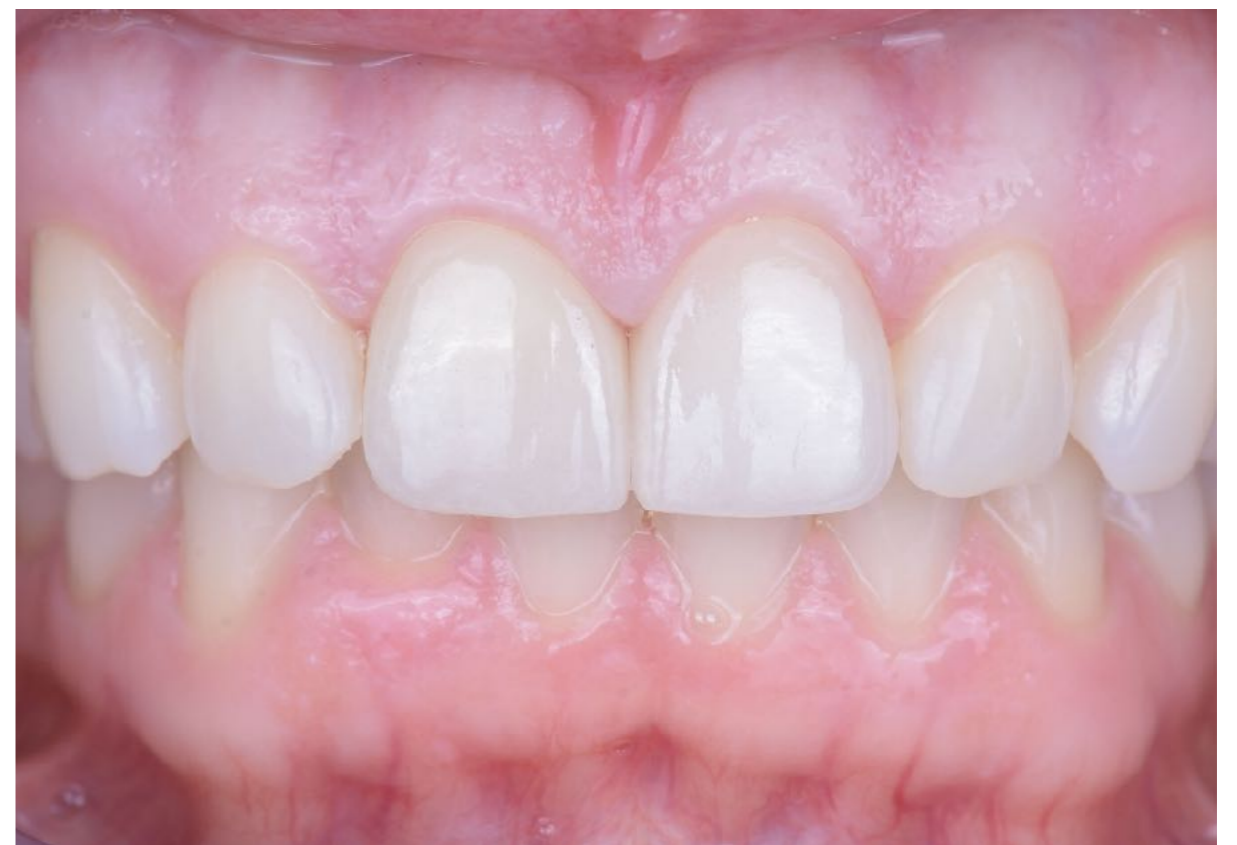What other transformations are possible?

Veneers can be used on a limited basis. Even one can brighten and rejuvenate a smile tremendously.

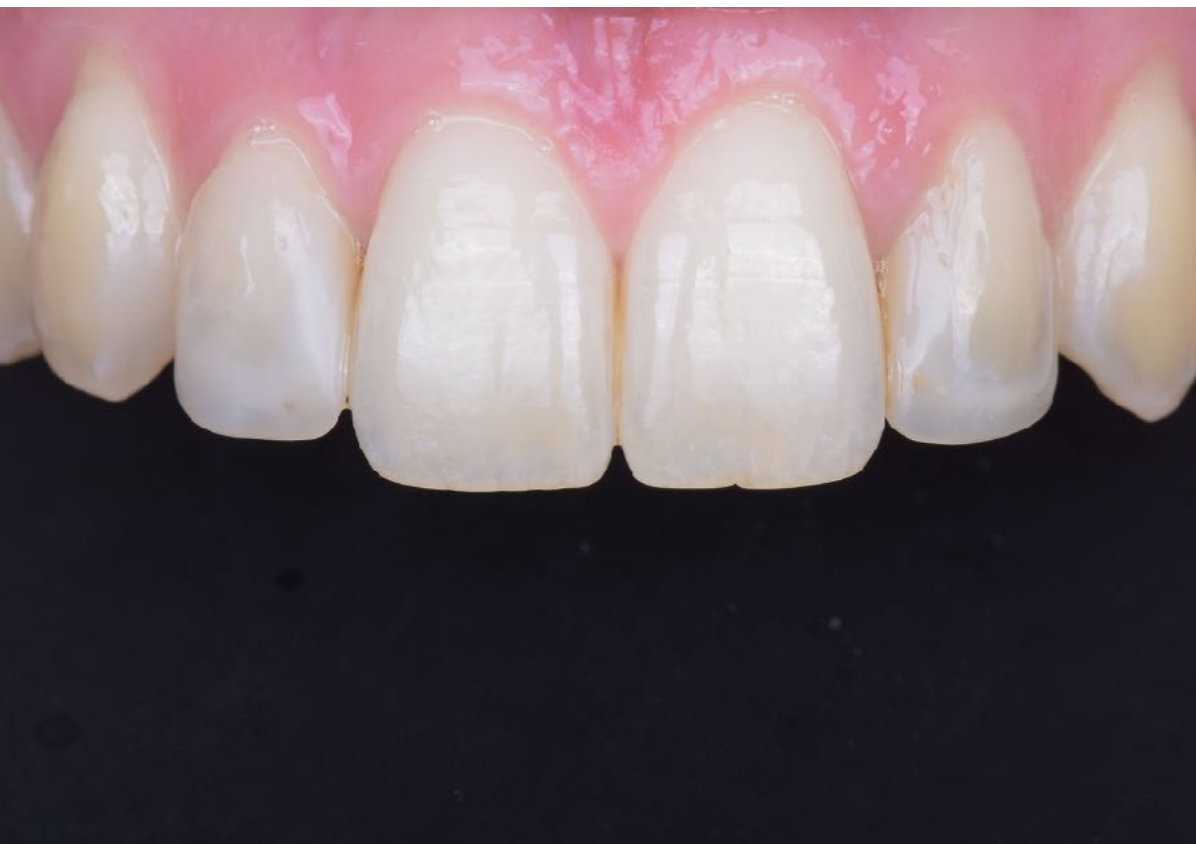



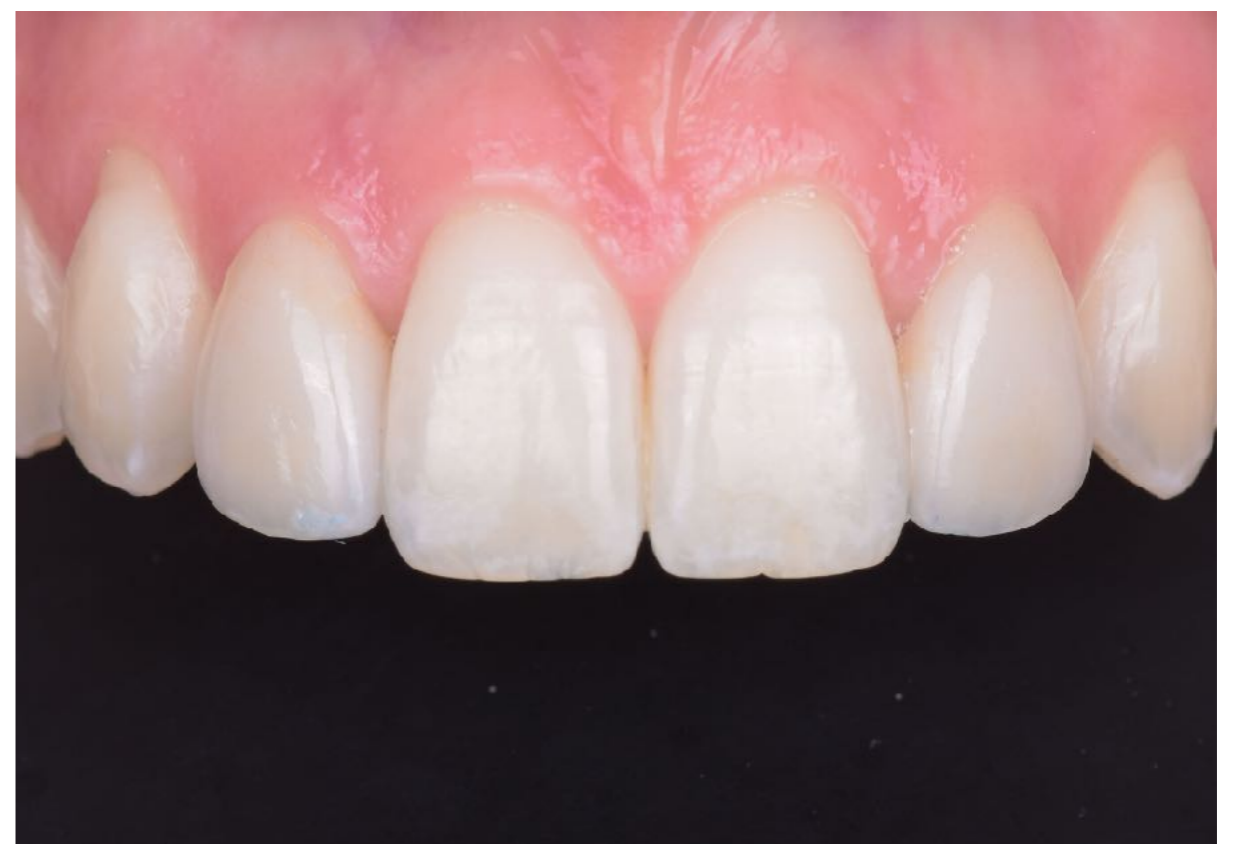Before



After



Before

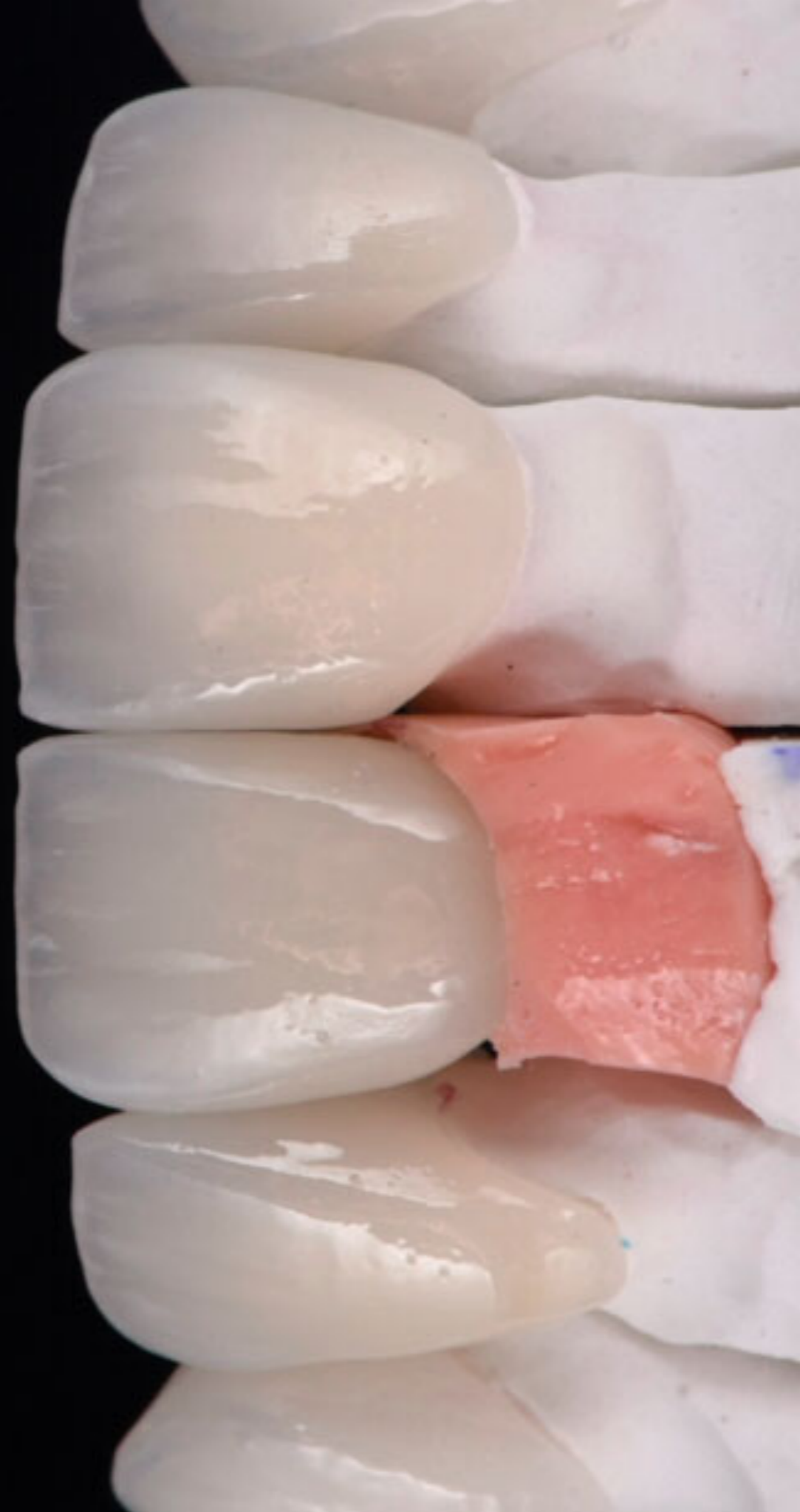

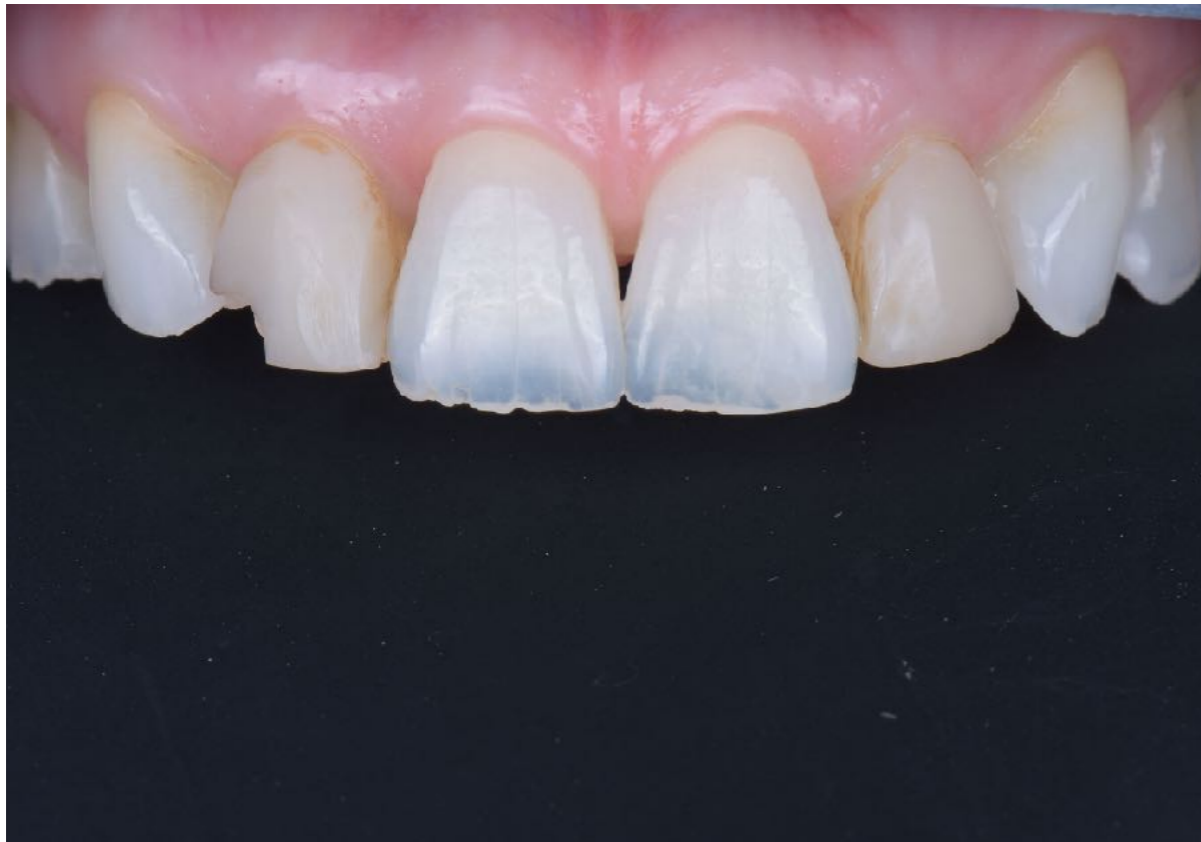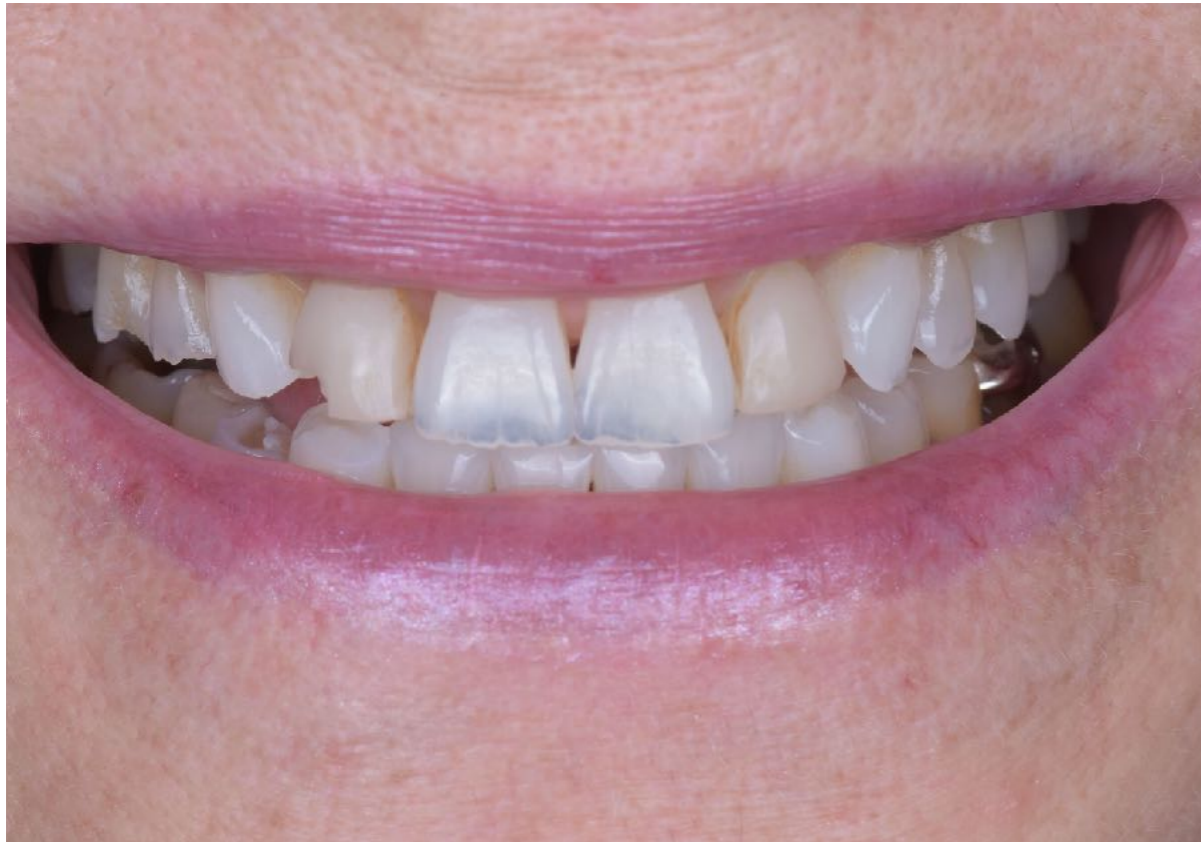After

COMPLEX

TRANSFORMATIONS

- Involve the restoration of worn, missing, or compromised dentition
- Only one or both dental arches might be involved in the treatment, often with dental implants



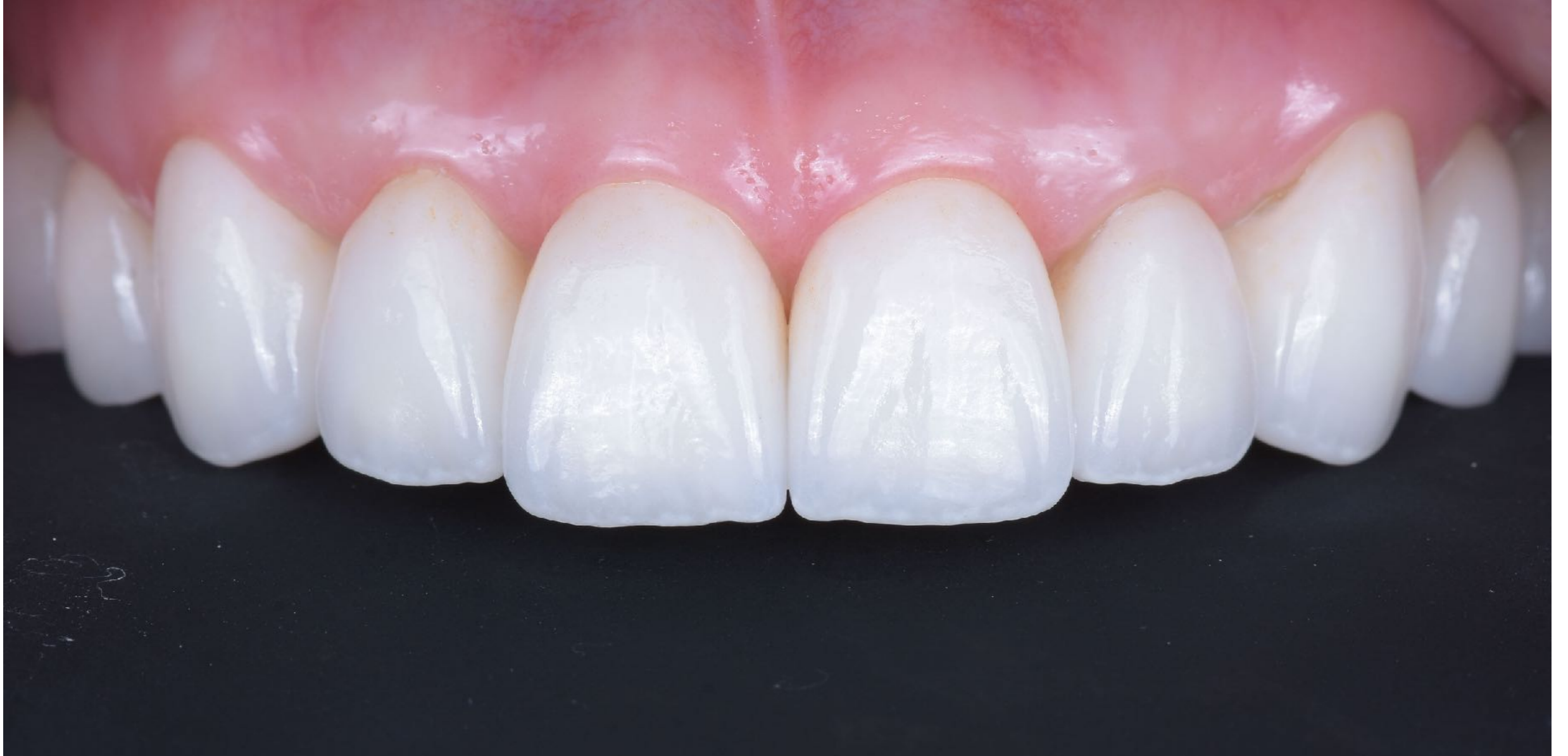
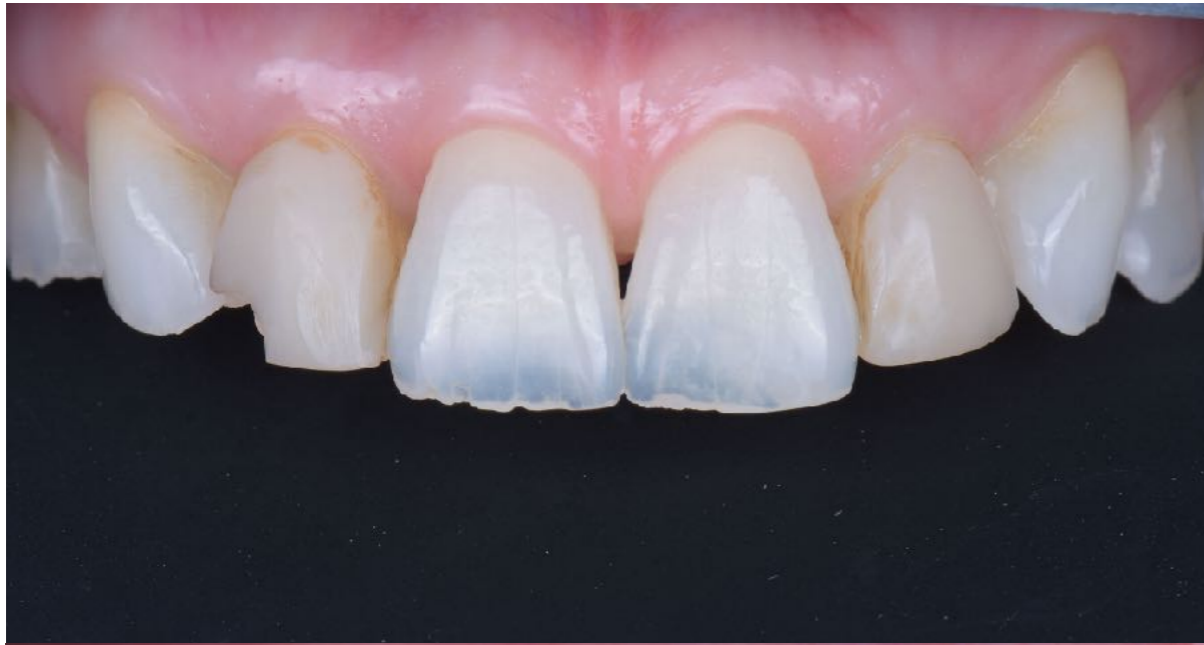
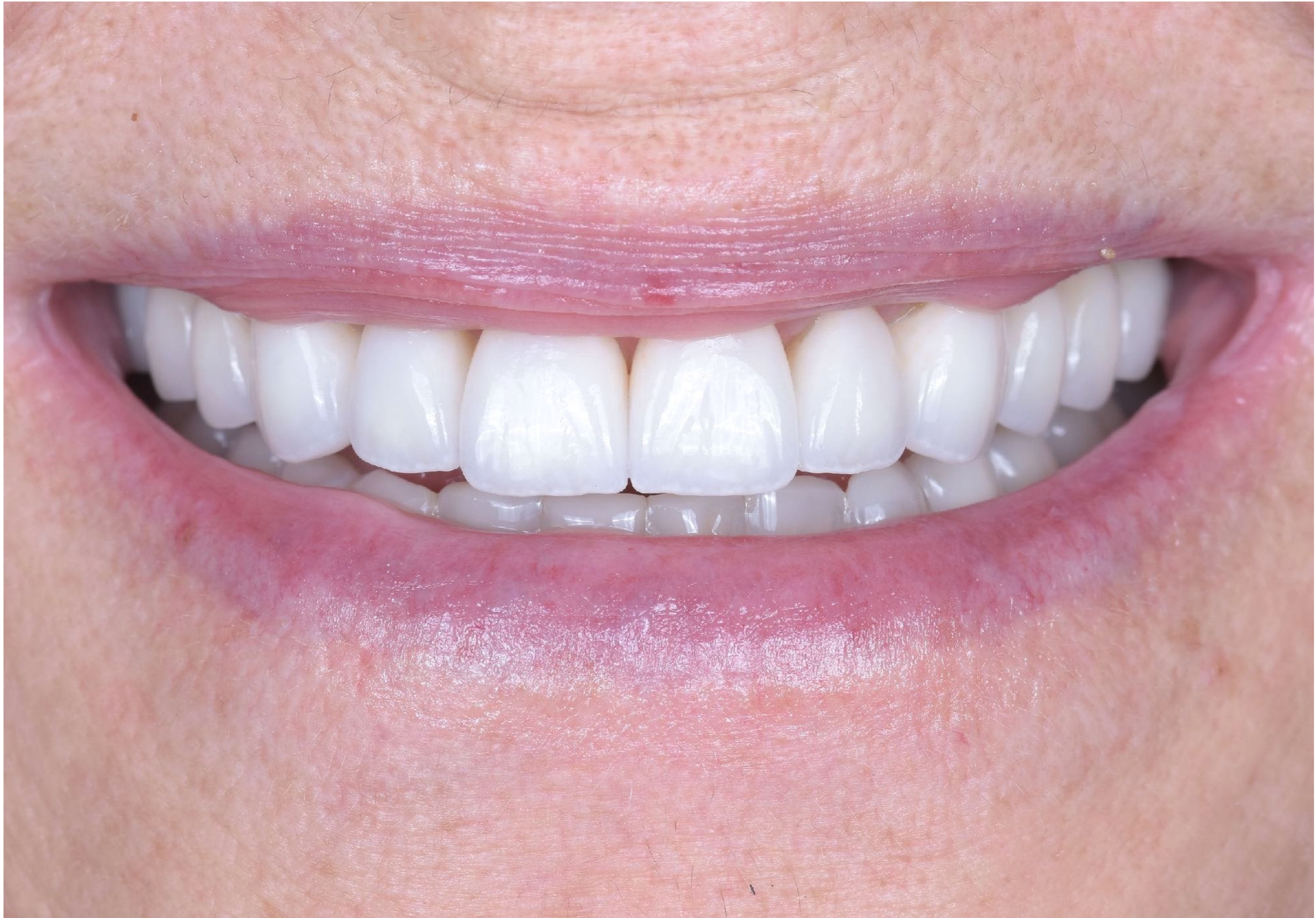Full mouth transformation

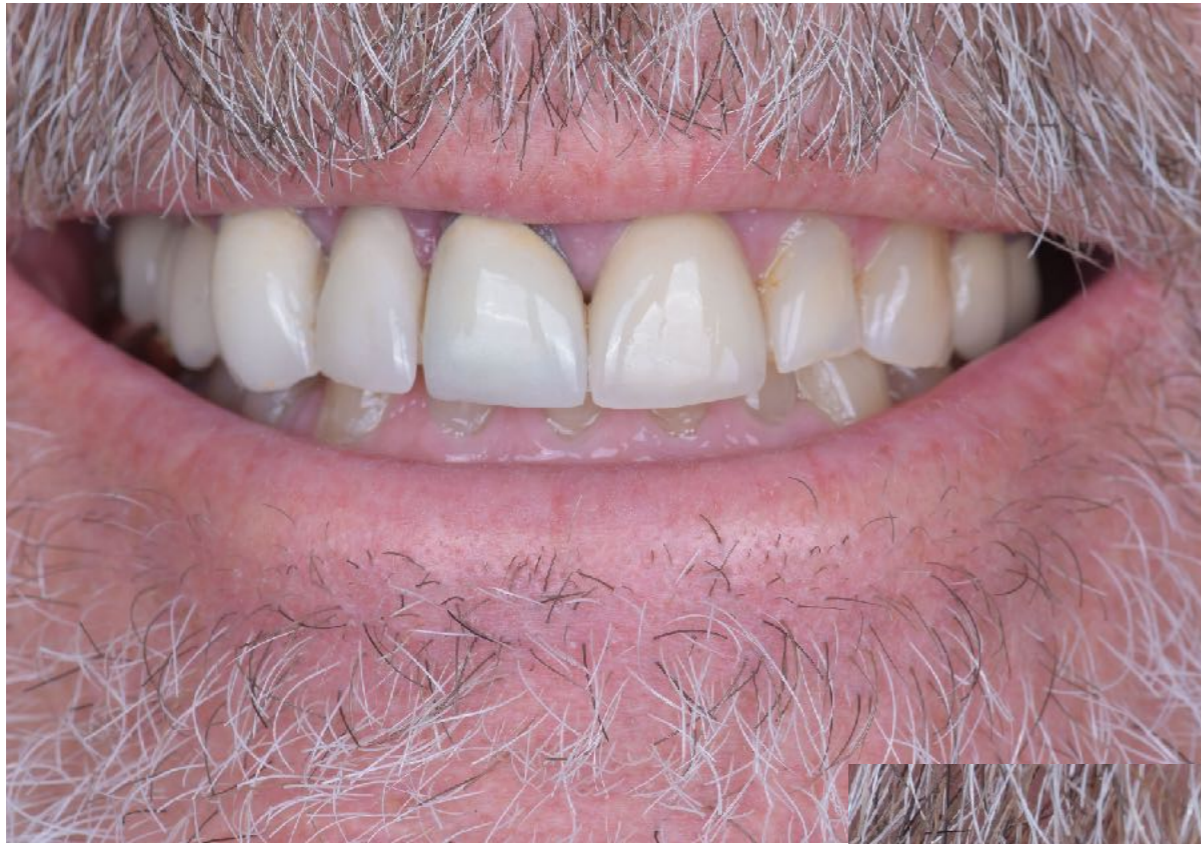The patient had worn her teeth down and wanted to achieve a brighter and more youthful smile.

Notice the thin and rugged edges of the front teeth due to the wear.

A full mouth transformation was completed using veneers, crowns, and partial crowns.



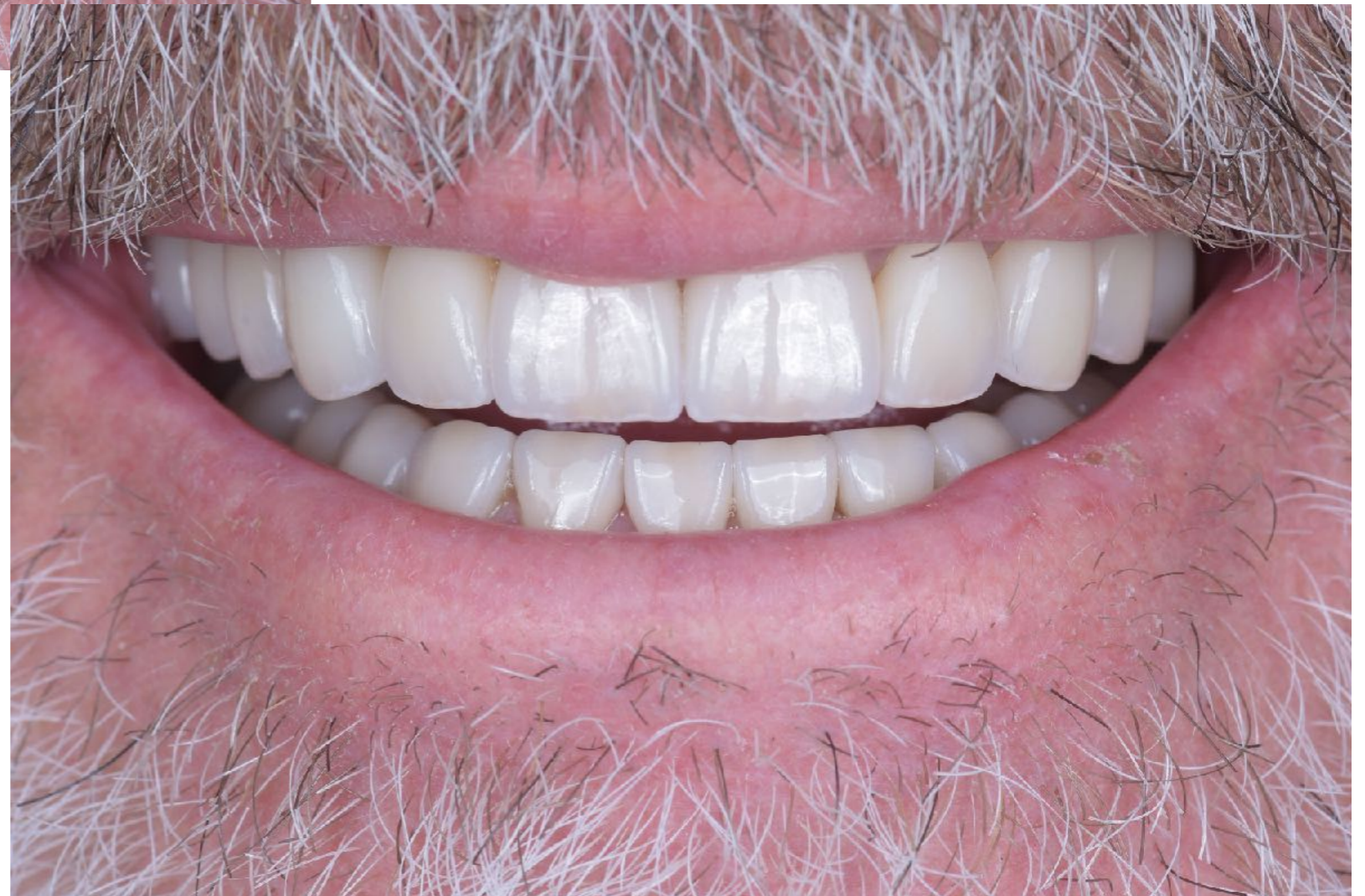



Full mouth transformation

This gentleman wanted to update his smile with the latest material technology. Being a public speaker, he understands the importance of a "great" first impression, and the smile is a big part of it.

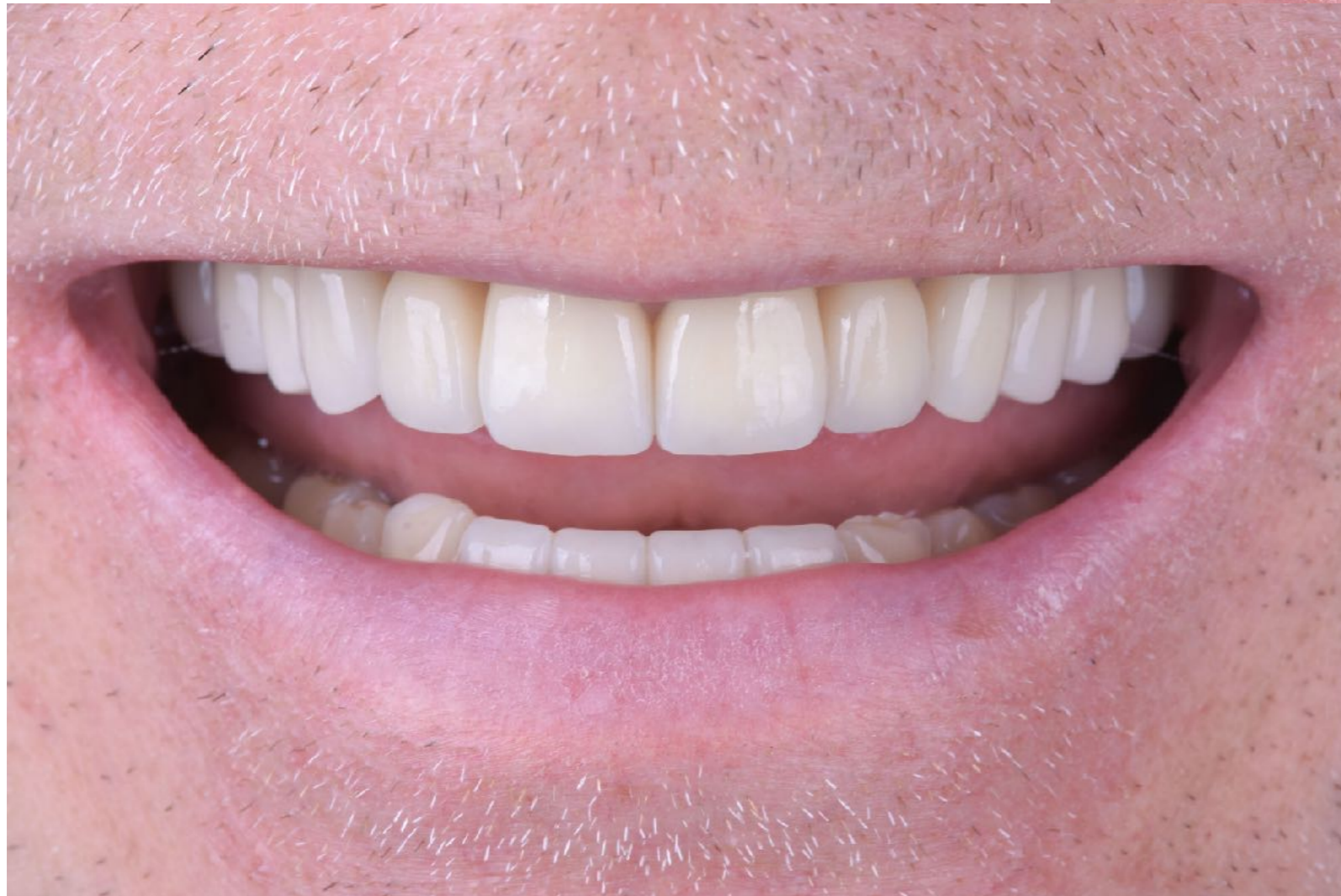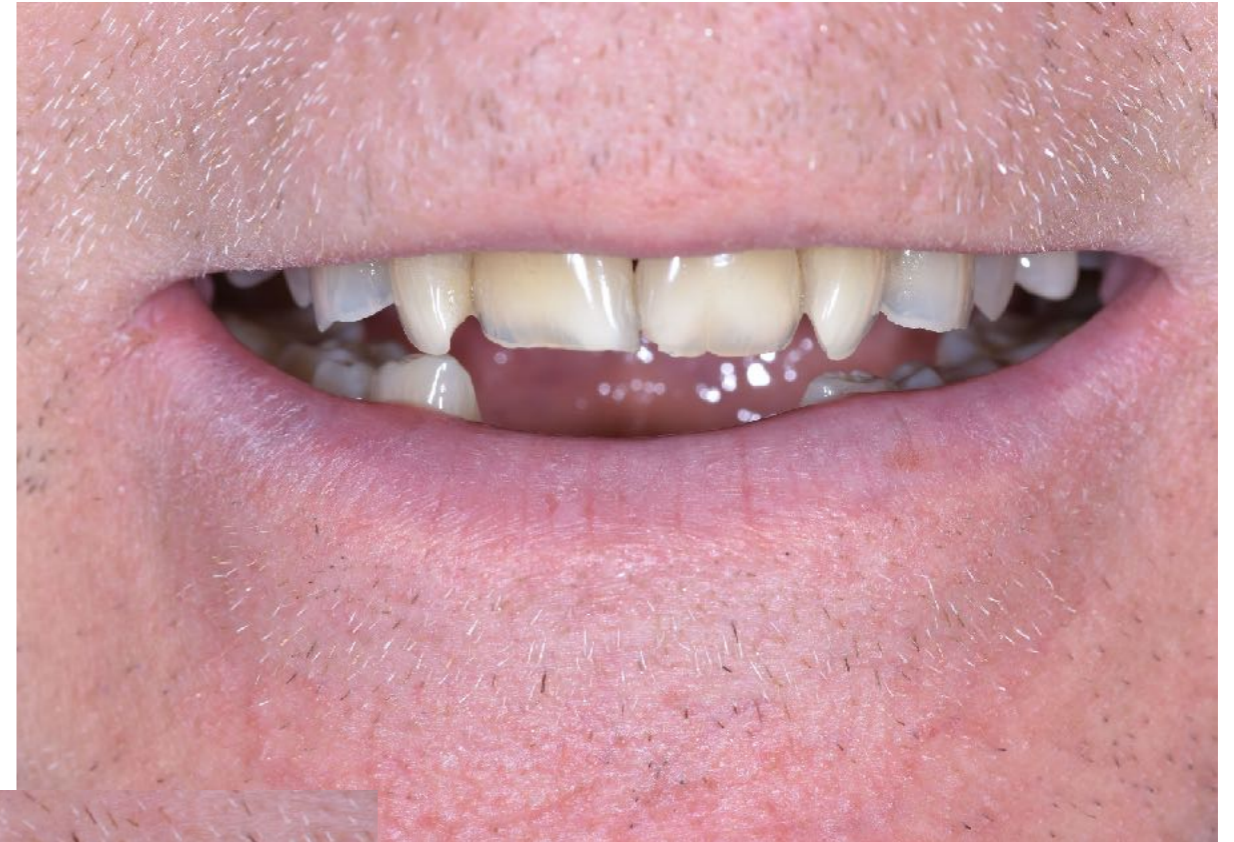A combination of porcelain crowns and veneers were used.



Full mouth transformation

This gentleman was tired of not smiling on his family photos!

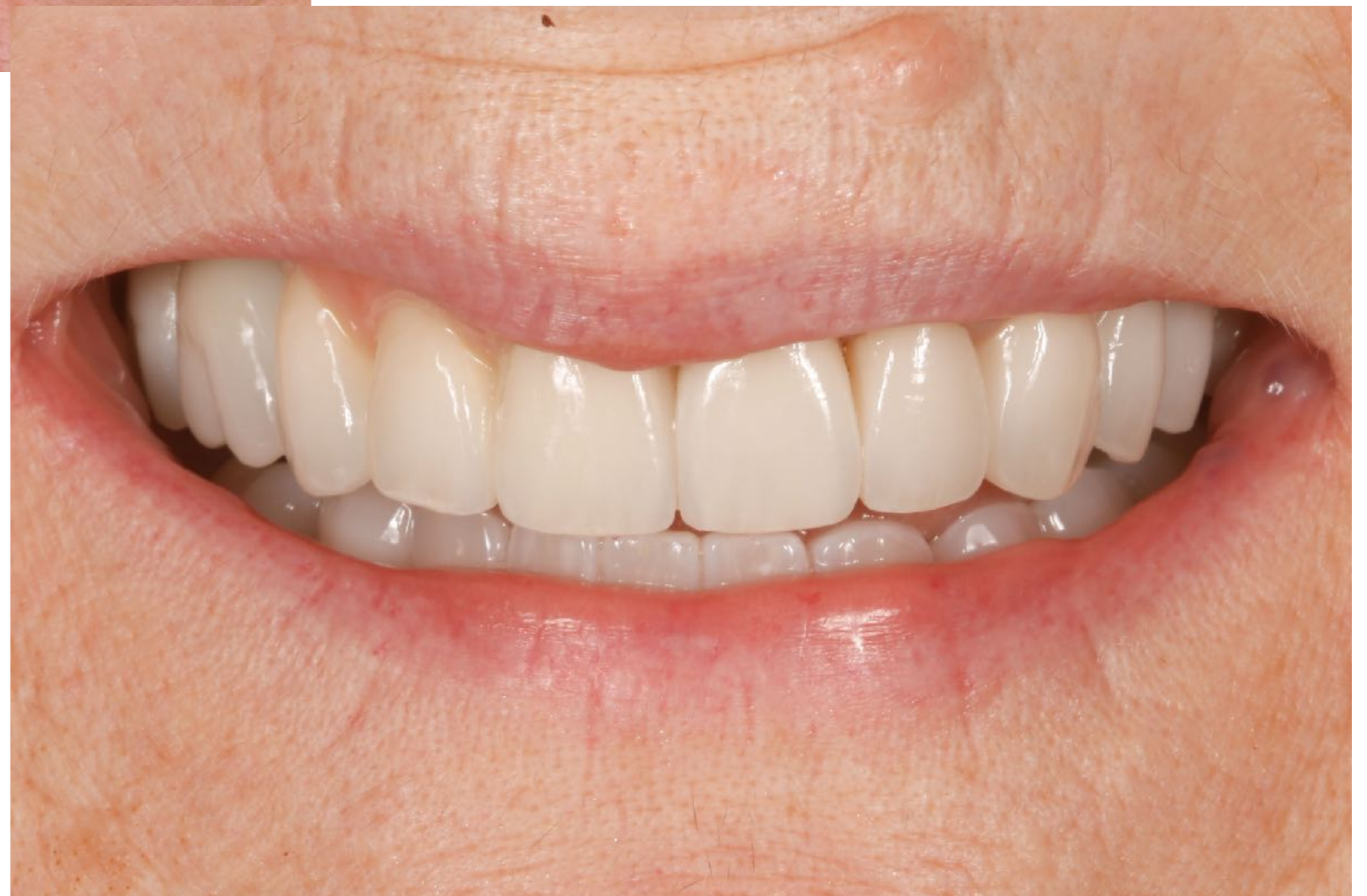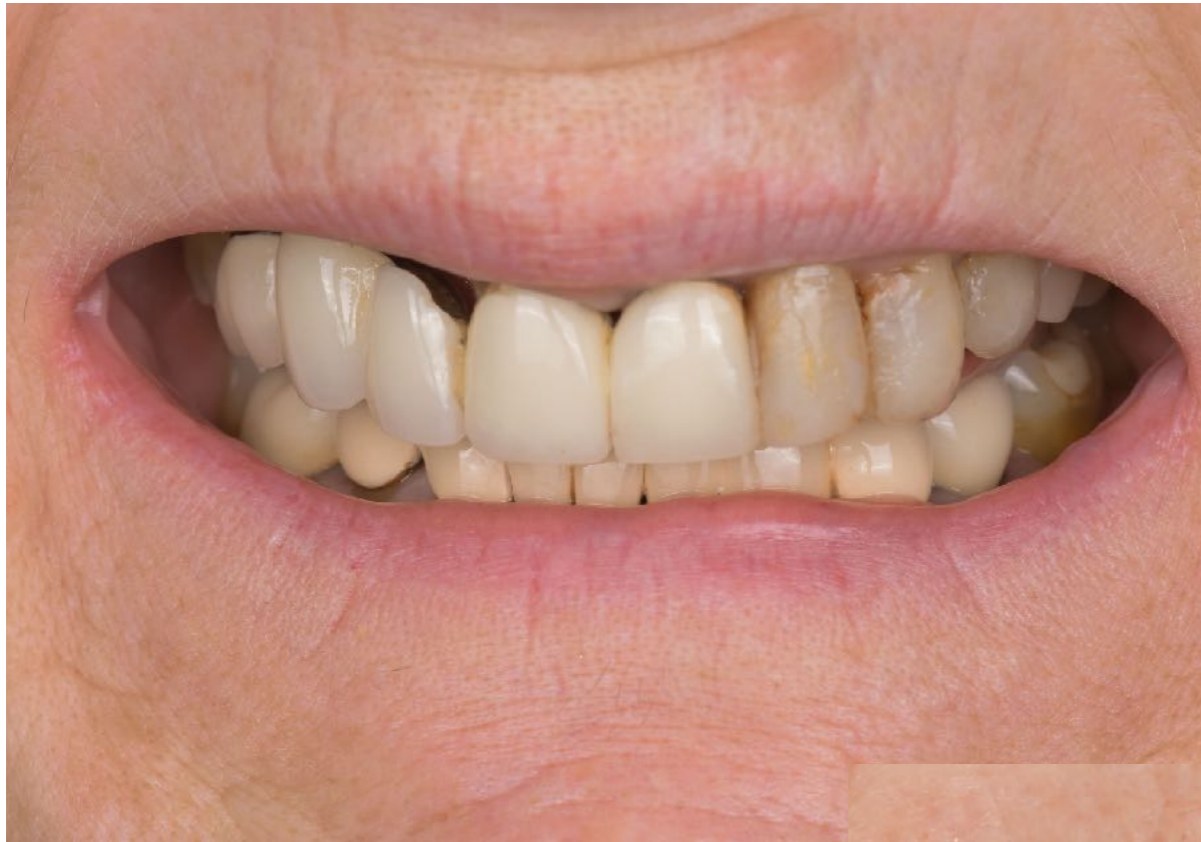We completely change the shape, size, alignment and dramatically improve the smile.



Full mouth transformation

This lovely lady was not happy with her smile and her old crowns/FPD. Also several teeth had discoloured, thus anaesthetic, composite restorations.

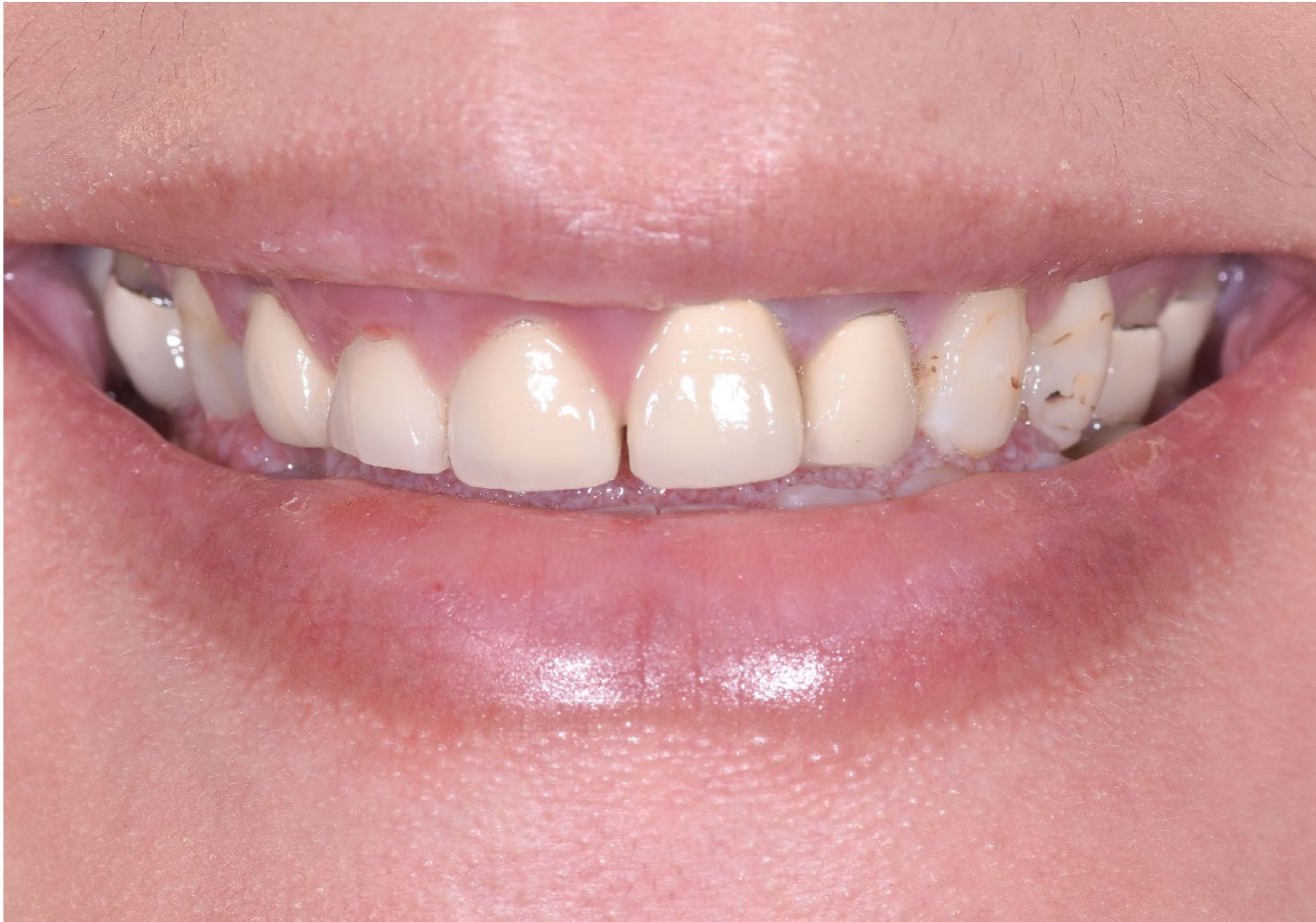A full mouth smile makeover was completed. Needless to say, she was very happy with the final result!

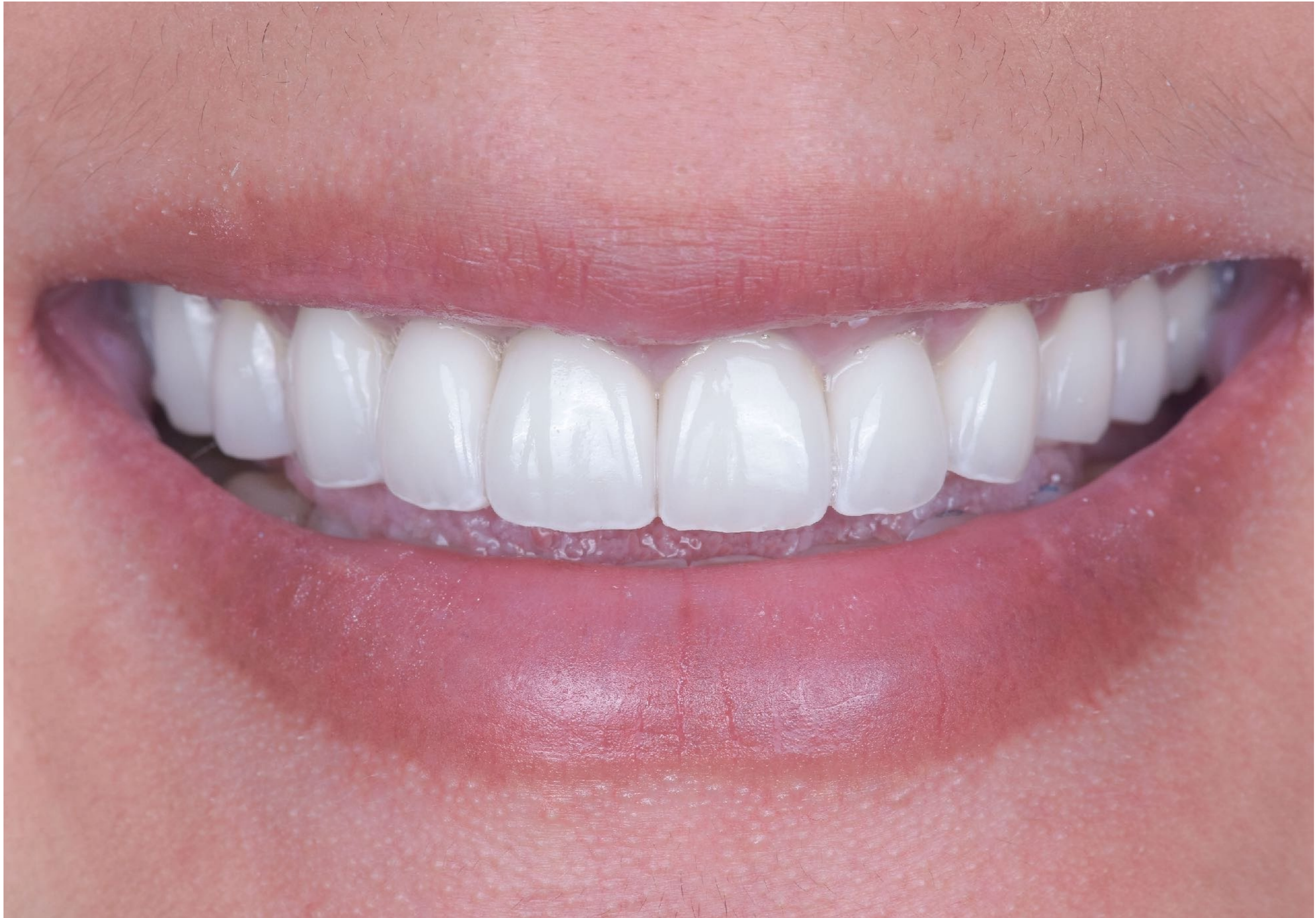

Full mouth transformation

The patient sought harmony of the soft tissue and to improve the colour and shape of her teeth..

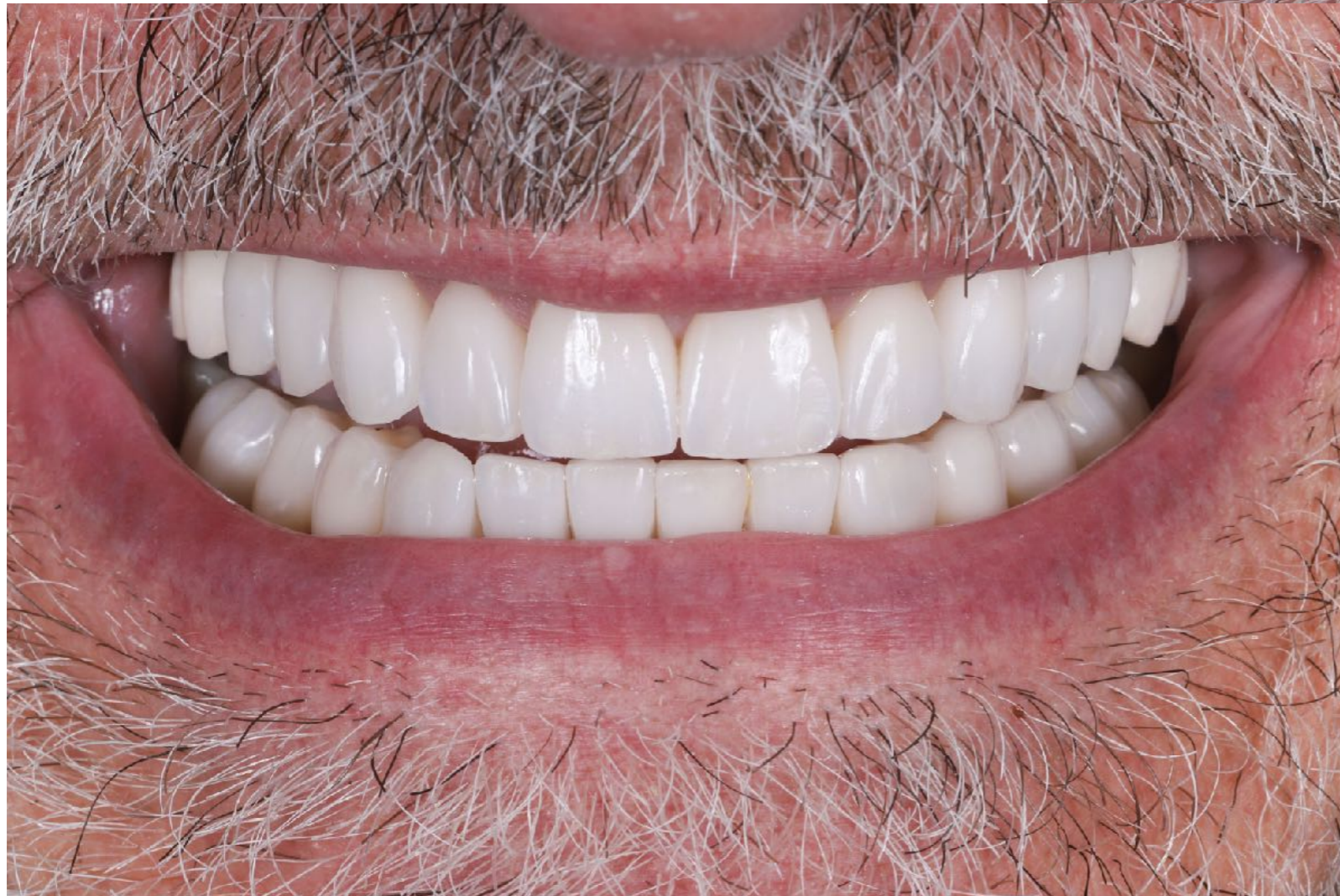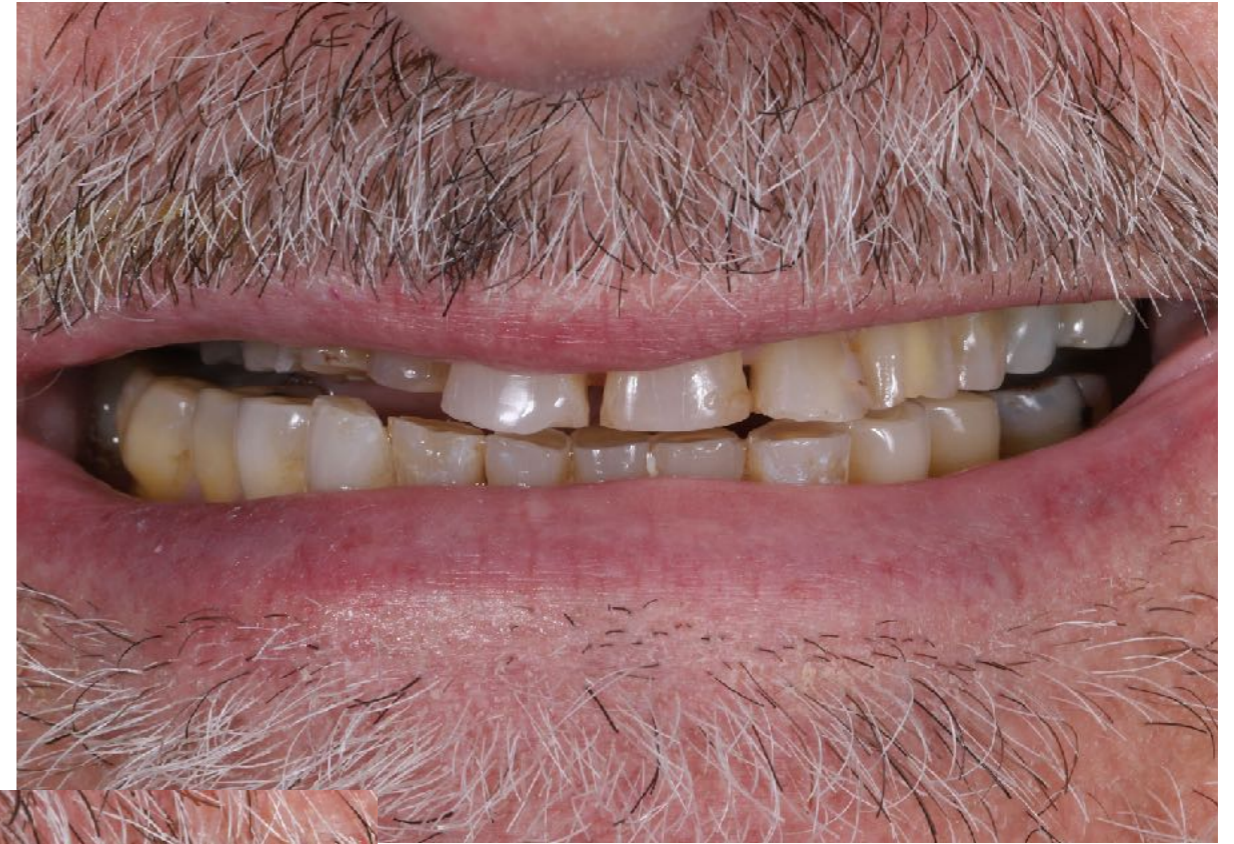We delivered a new bright and exciting smile, using, again, a combination of porcelain veneers and crowns.





Full mouth transformation

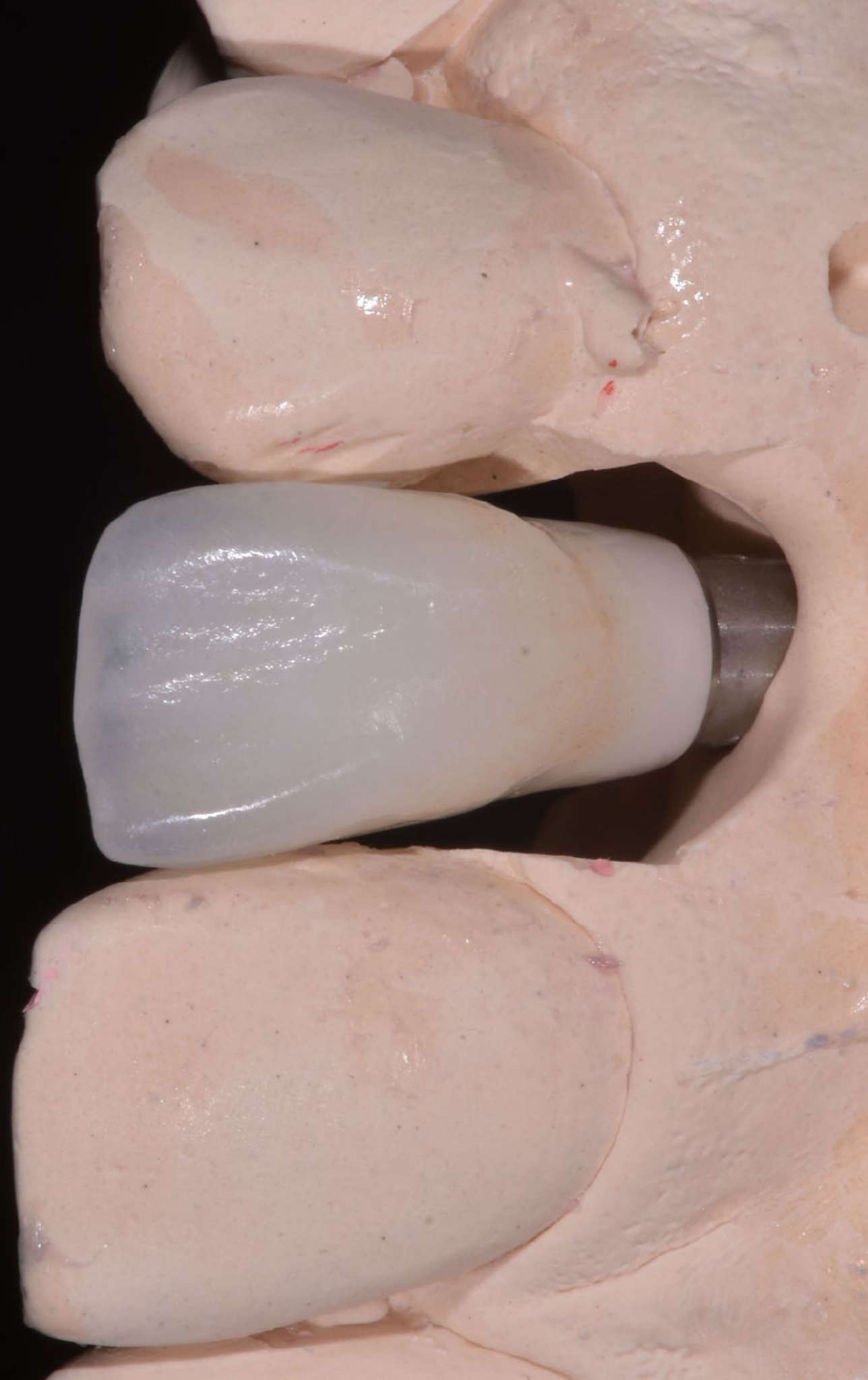
A complex rehabilitation to restore worn dentition

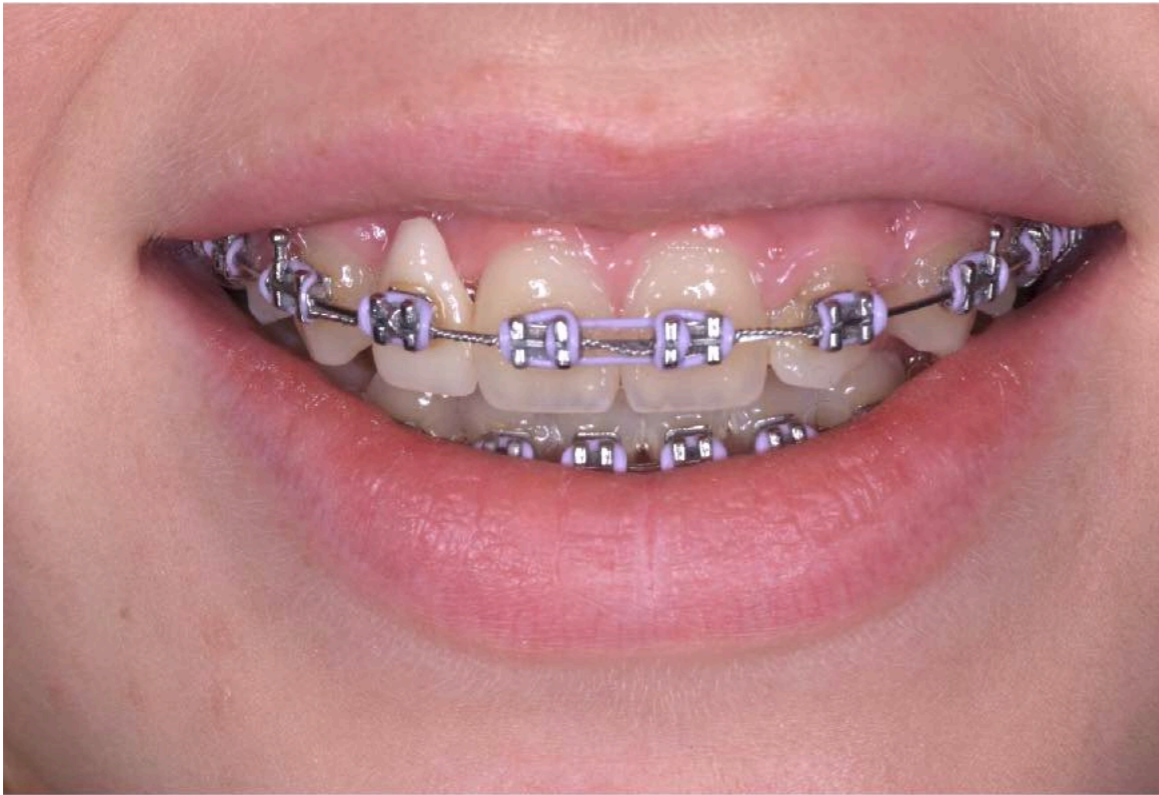


DENTAL

IMPLANTS

- The best replacement for missing teeth
- Proper planning and execution is necessary for the perfect aesthetic and function outcome

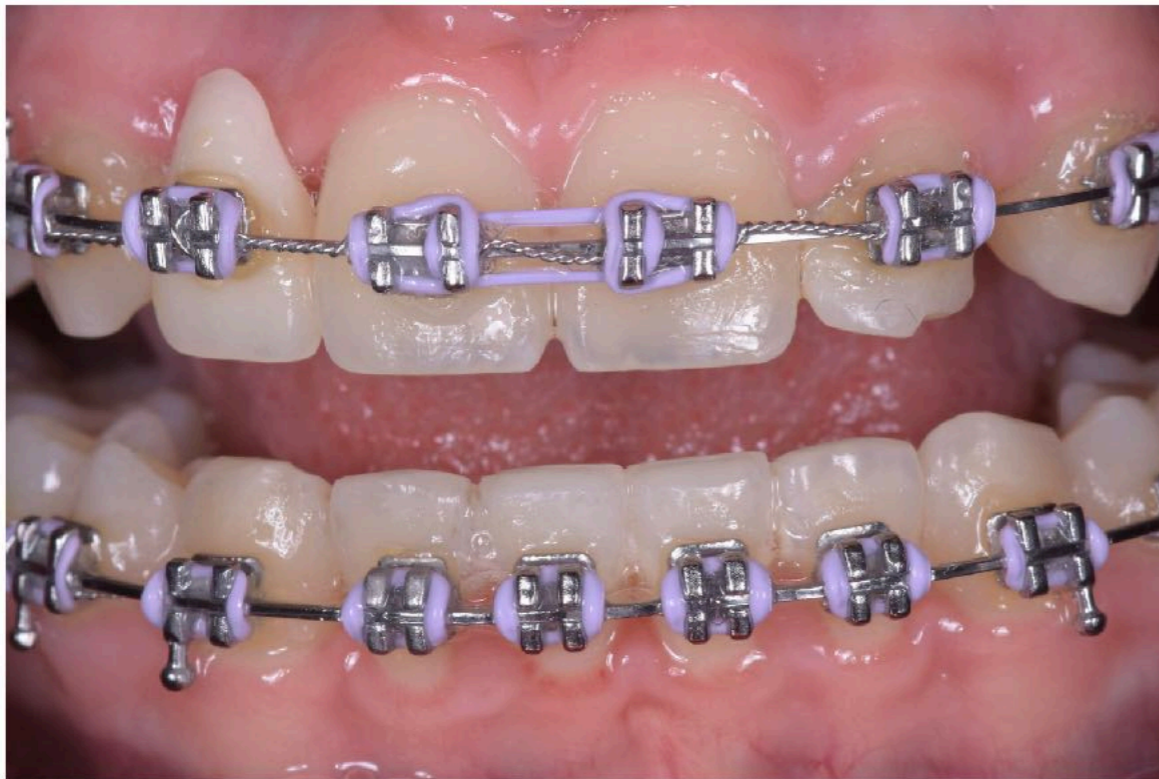



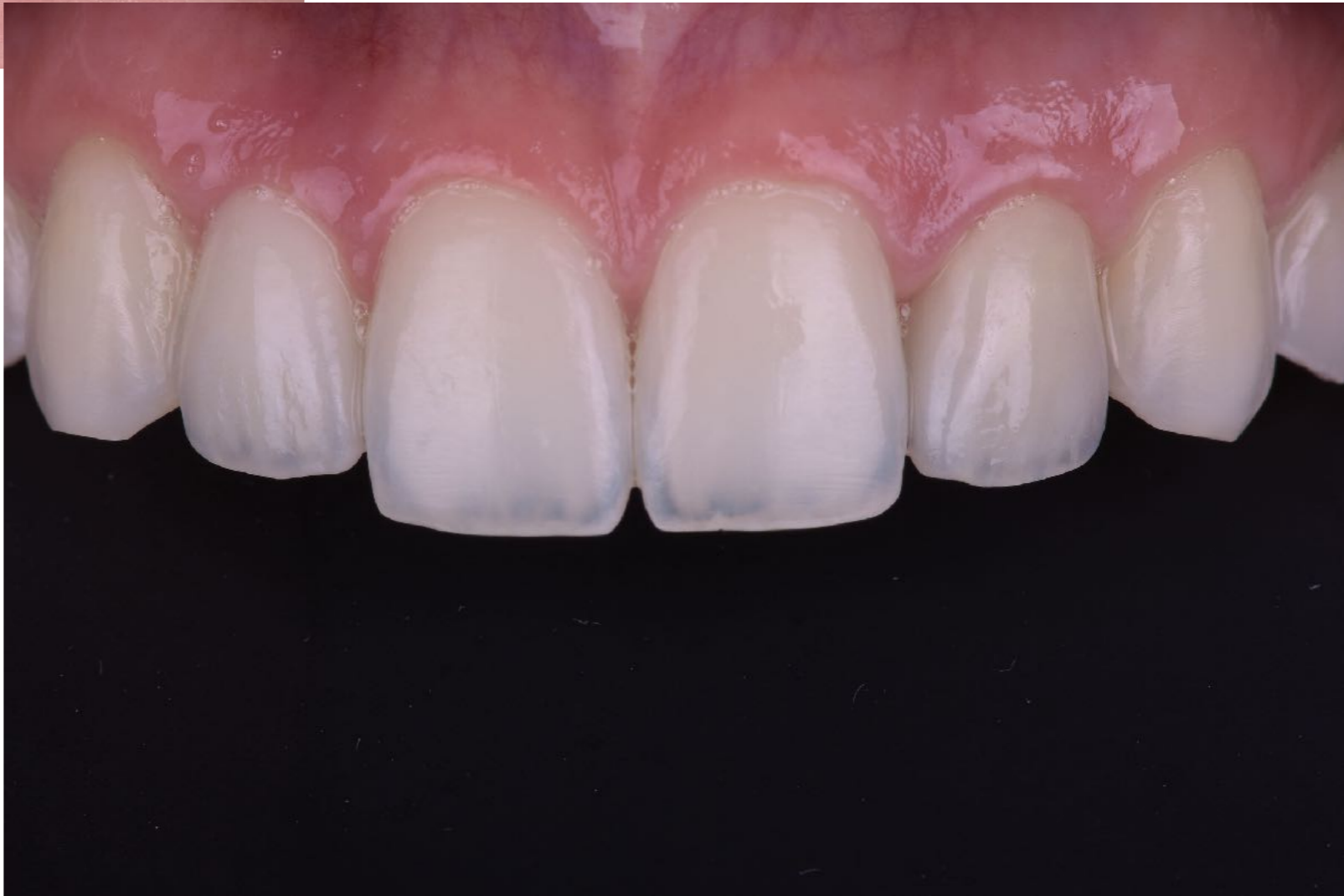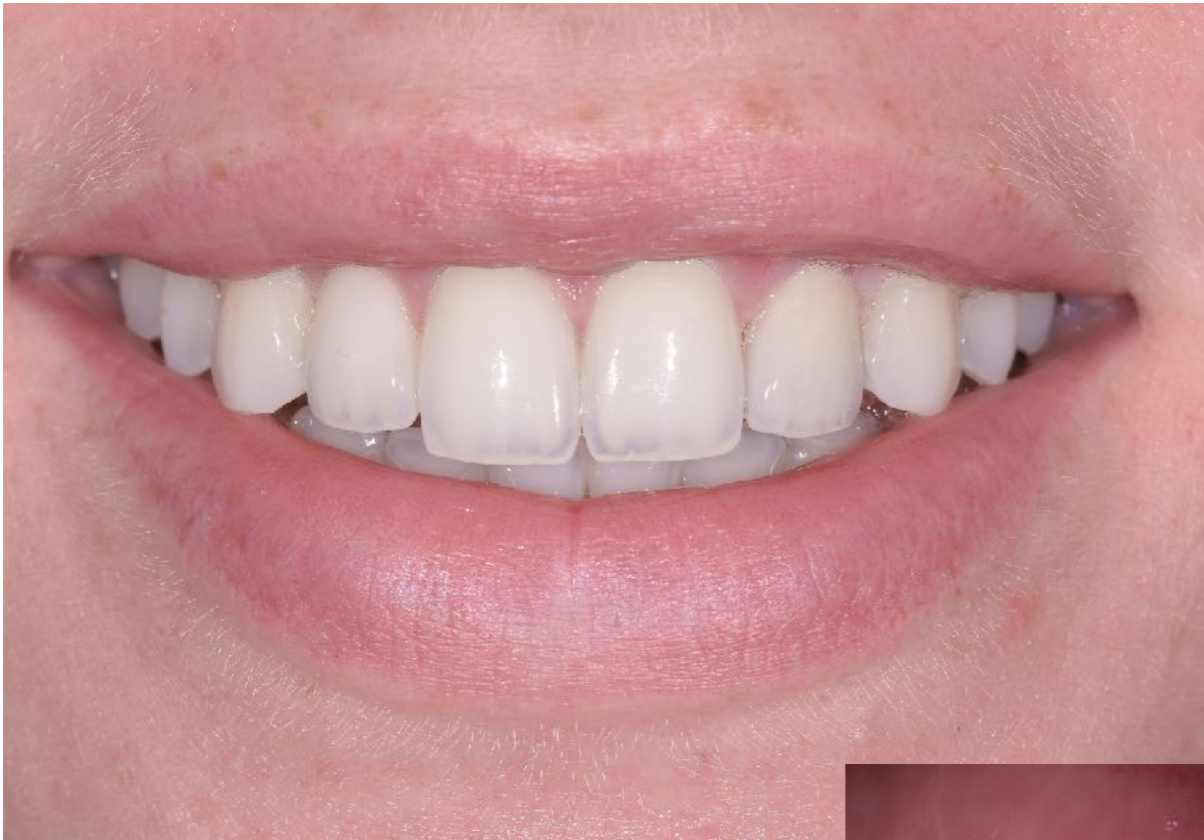Replacement of congenitally missing lateral

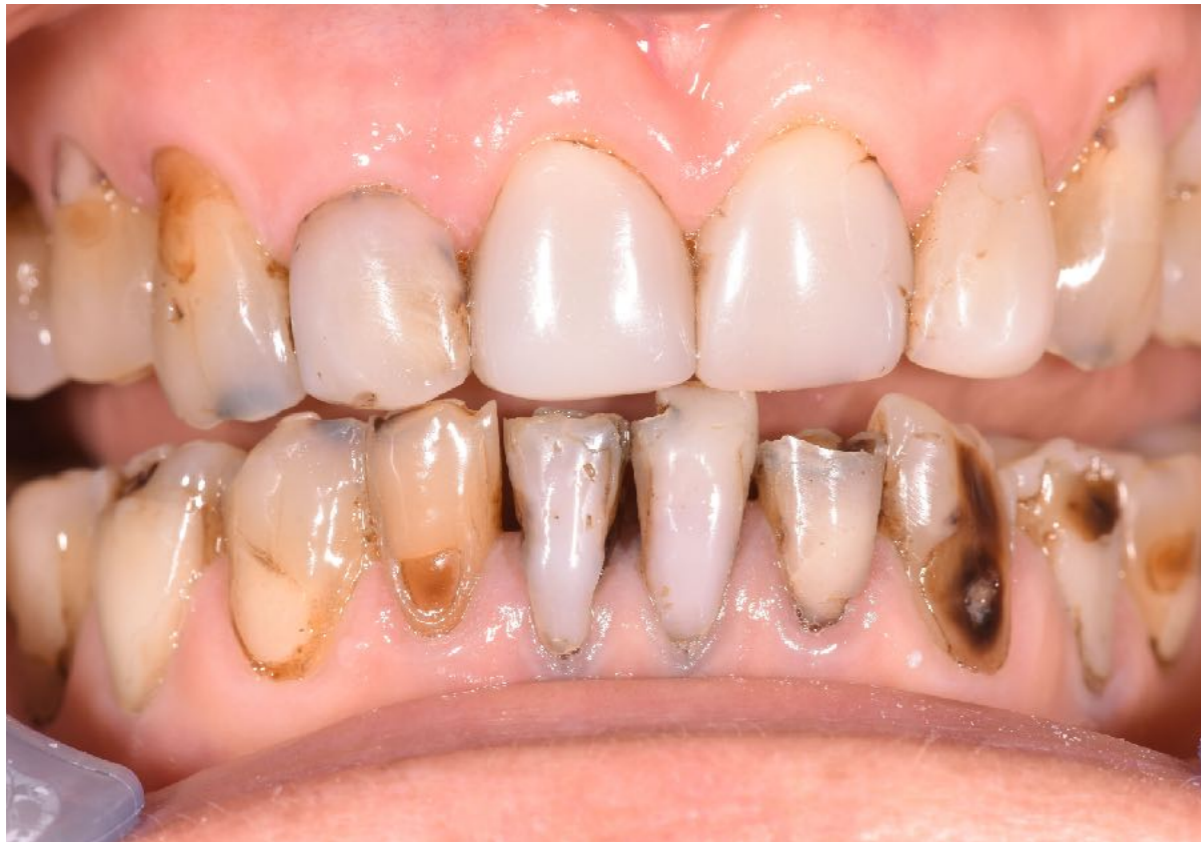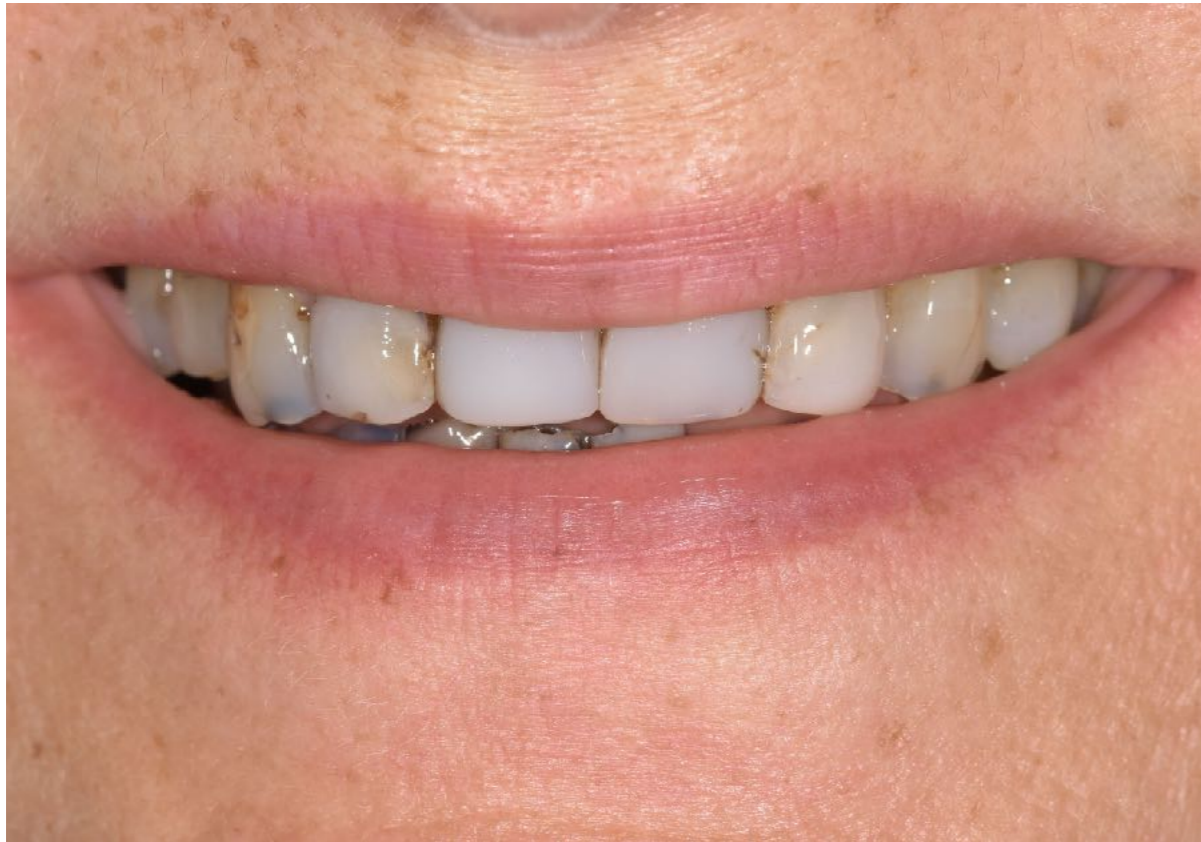This young lady had congenitally missing lateral; the other one was conoid.

Orthodontic treatment was done to create the proper space for the lateral replacement: a dental implant was planned in area #12, whereas a porcelain veneer on the conoid tooth #22.



A beautiful end result...

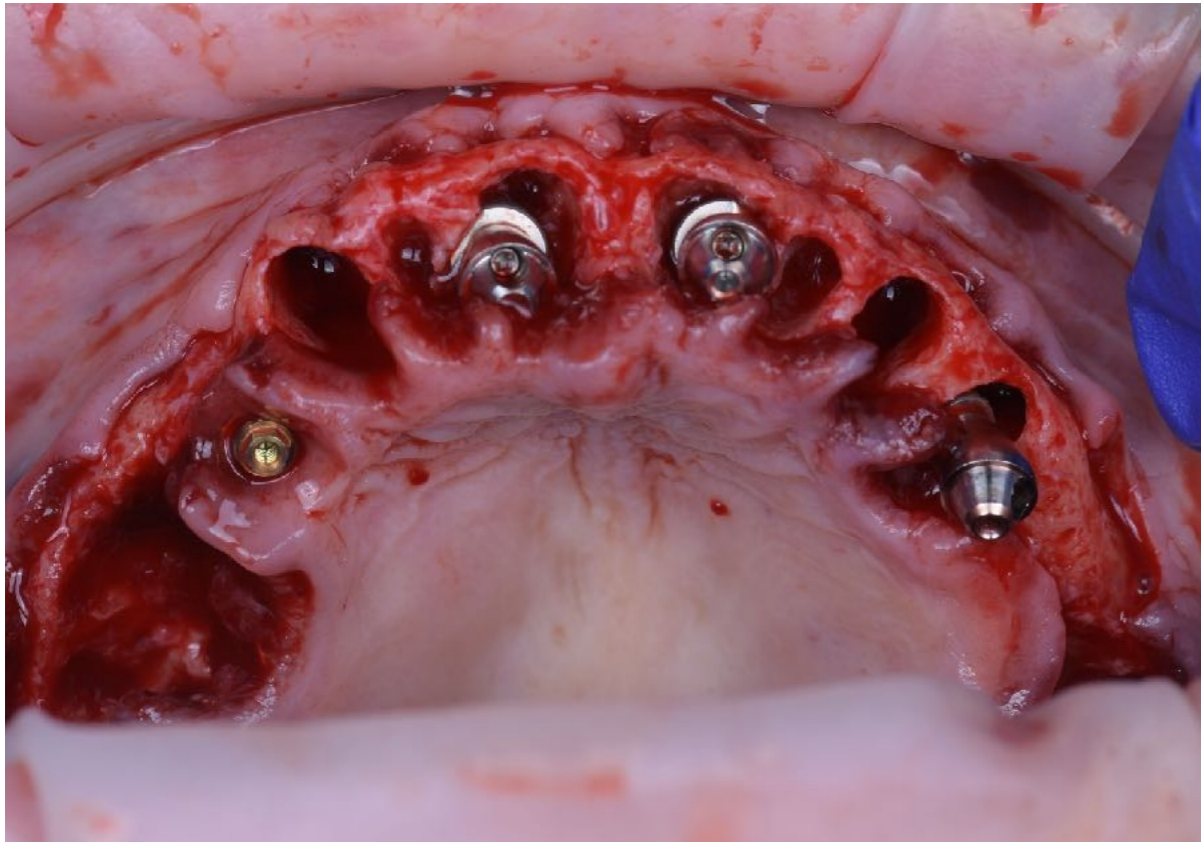




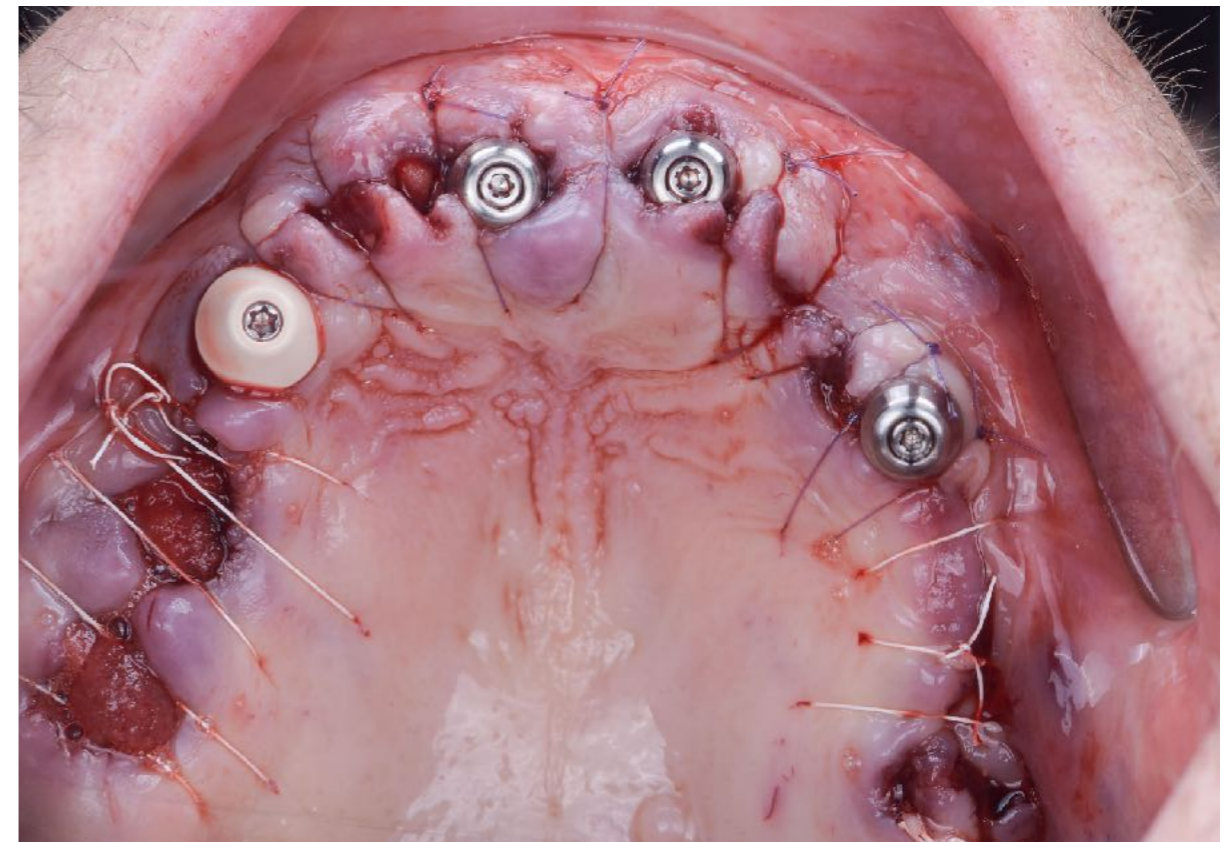All-On-X

This lovely patient presented with a failing maxillary arch due to periodontal disease. Few teeth could be kept, but they were not prosthetically helpful, thus, we decided for a full arch extraction and an all-on-4 type implant prosthesis.

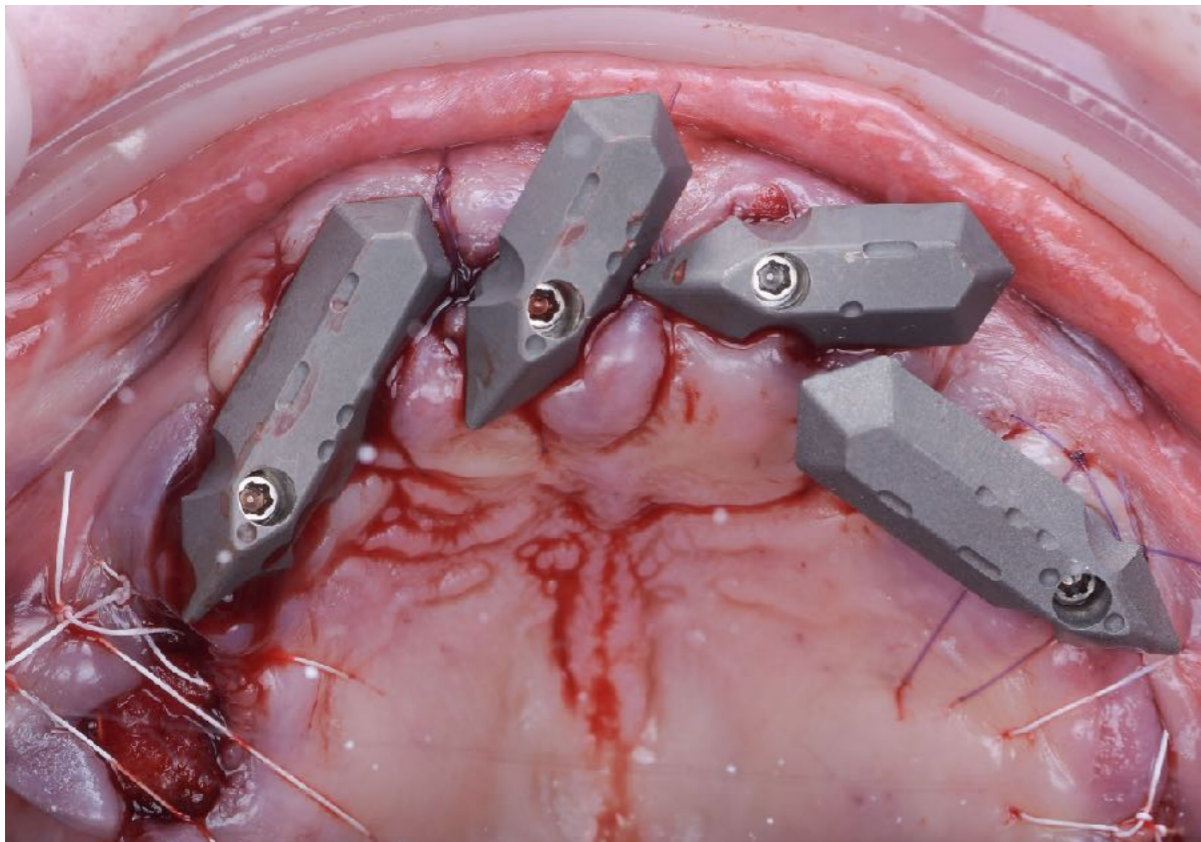
On the mandibular arch, a combination of tooth-supported crowns and implants was used.



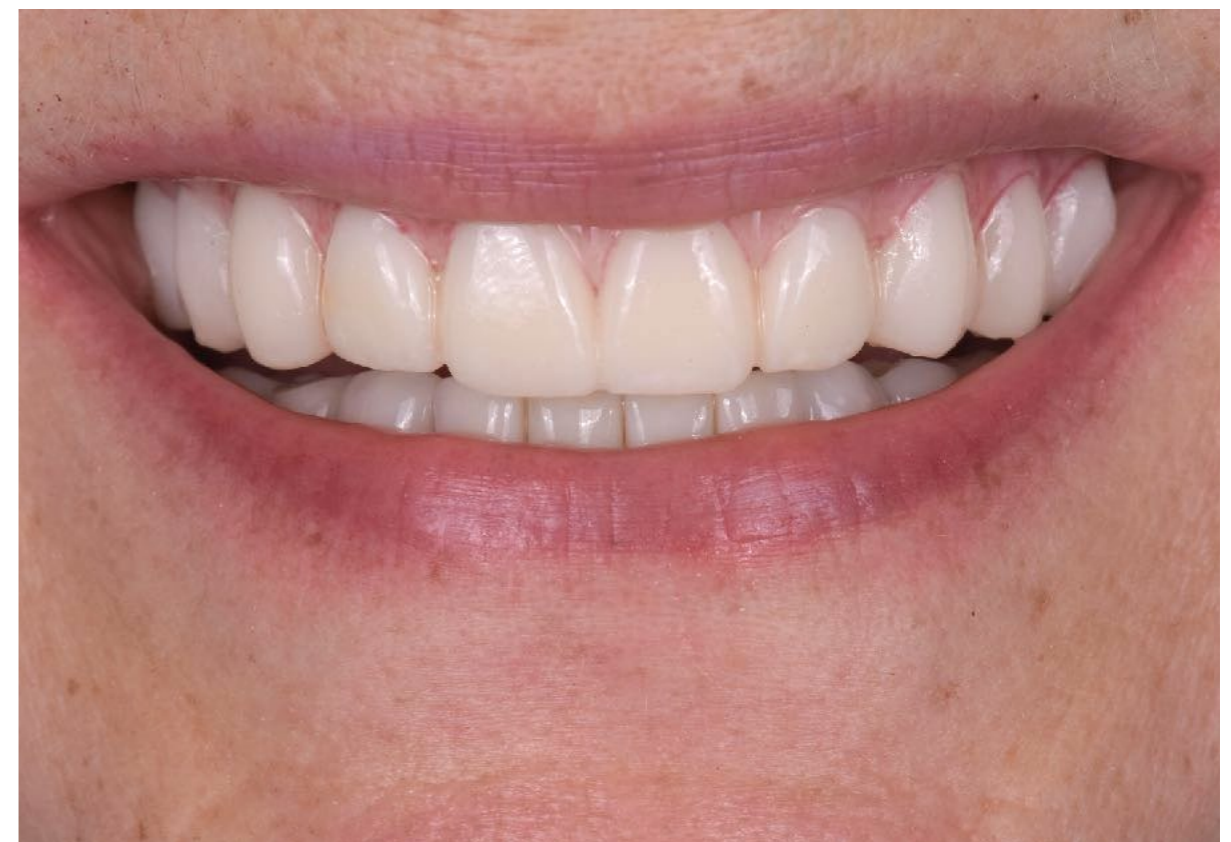Implants placed



Soft tissue sutured

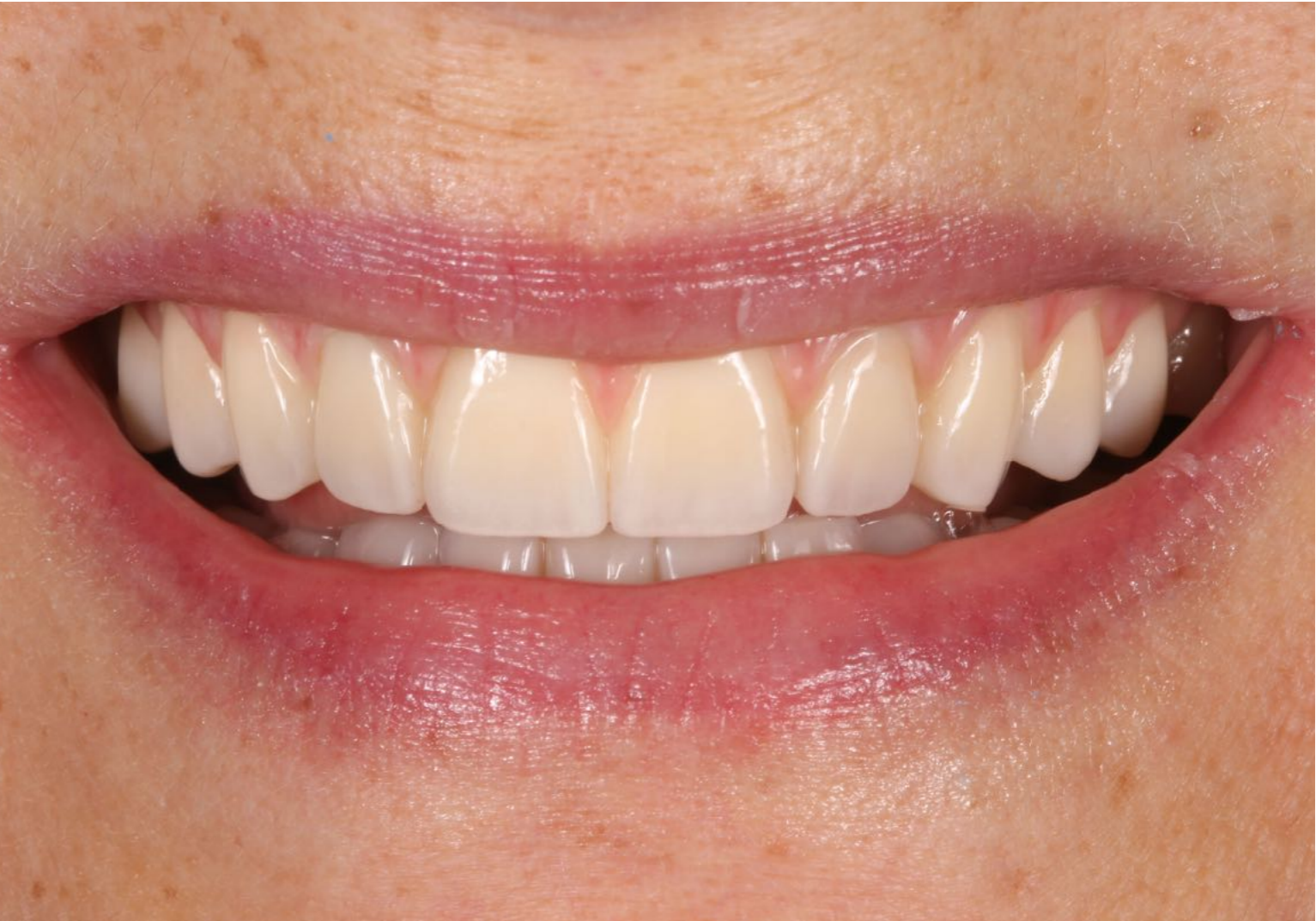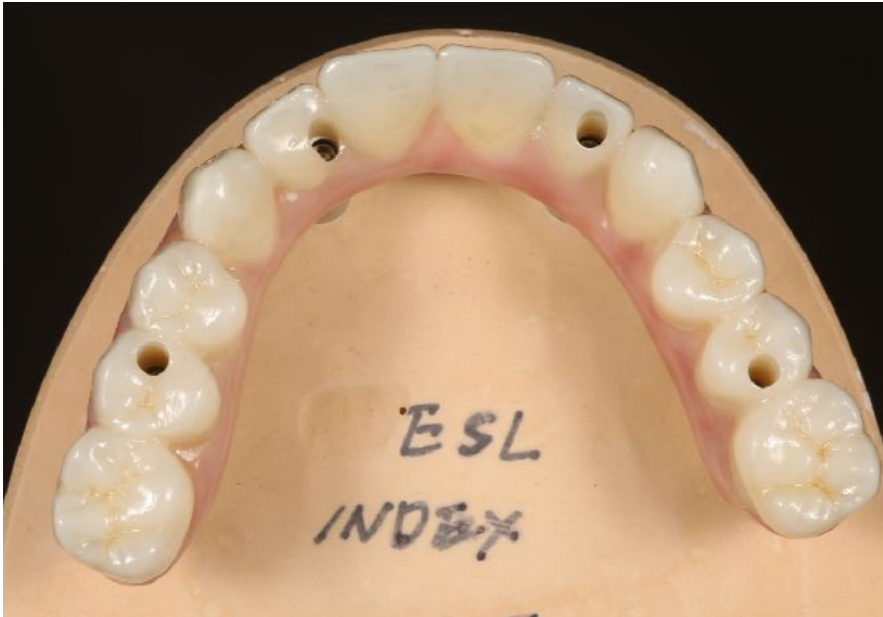

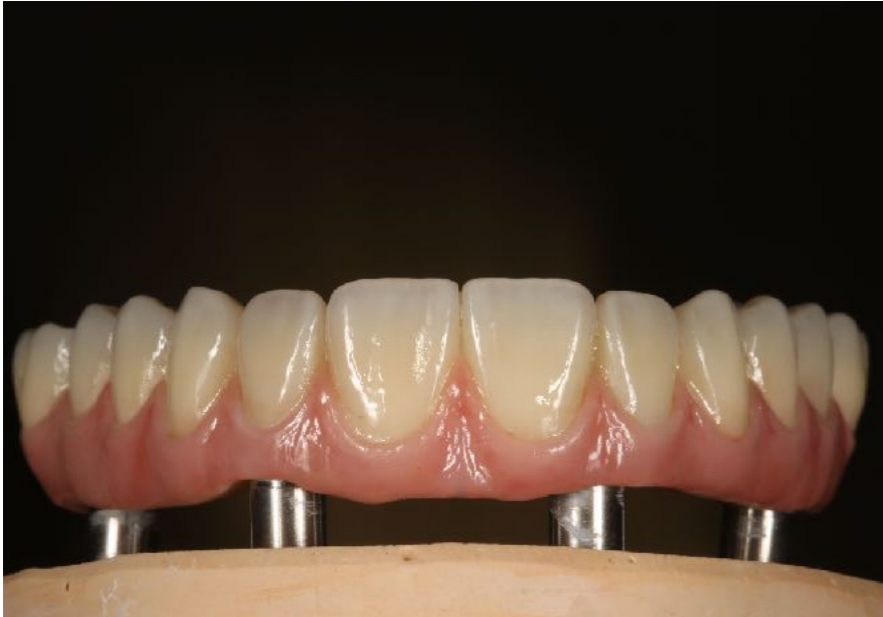
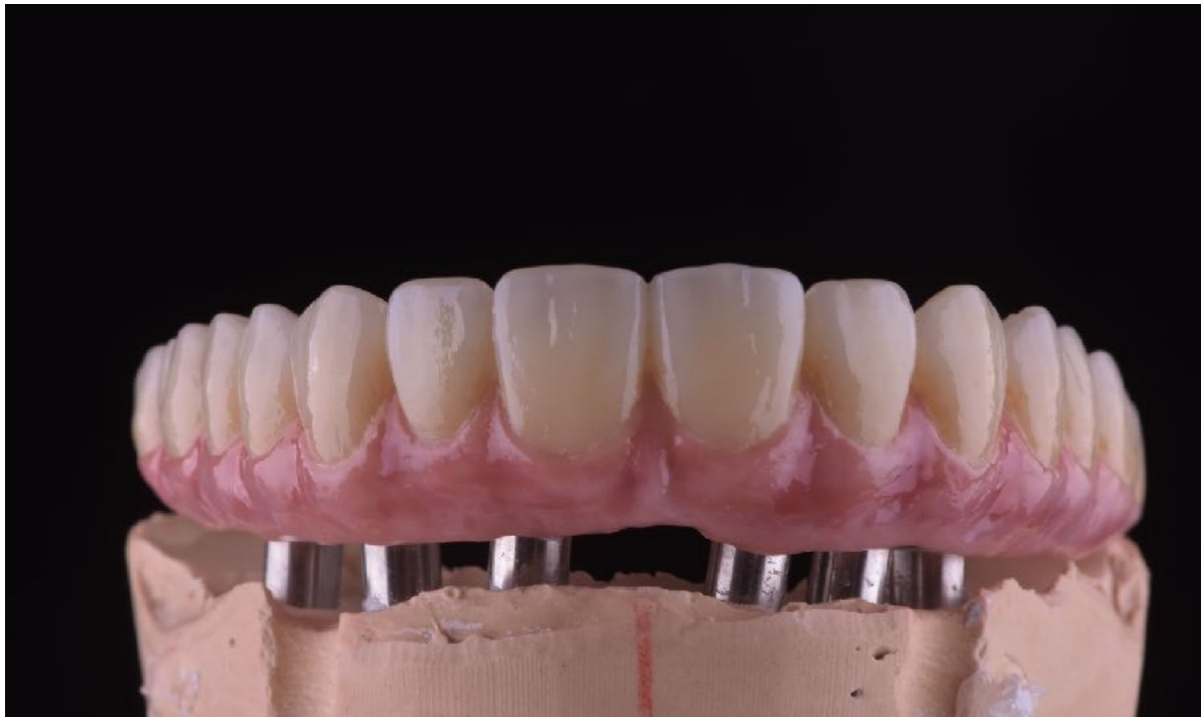Scan bodies



Same-day temporary delivery

Final prosthesis

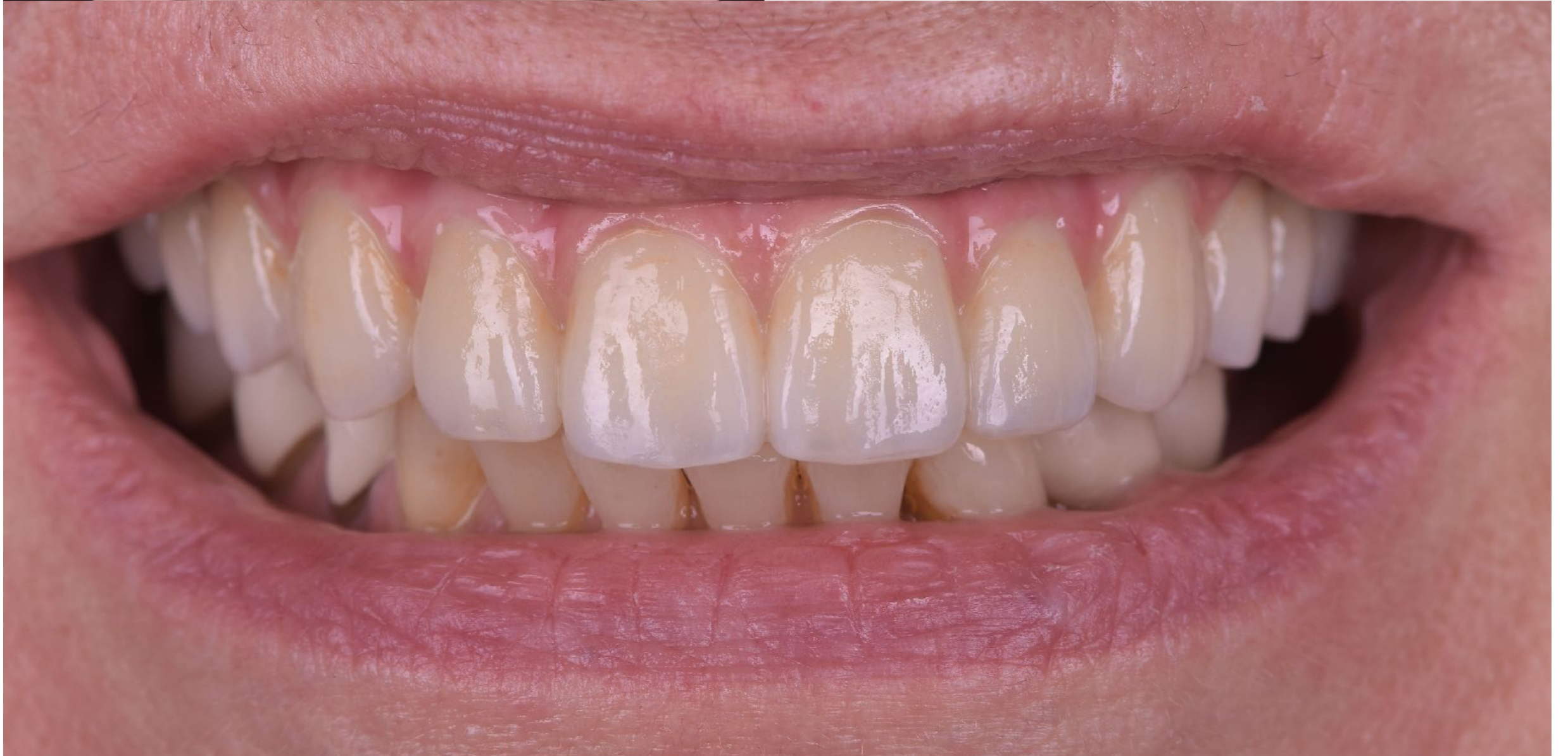


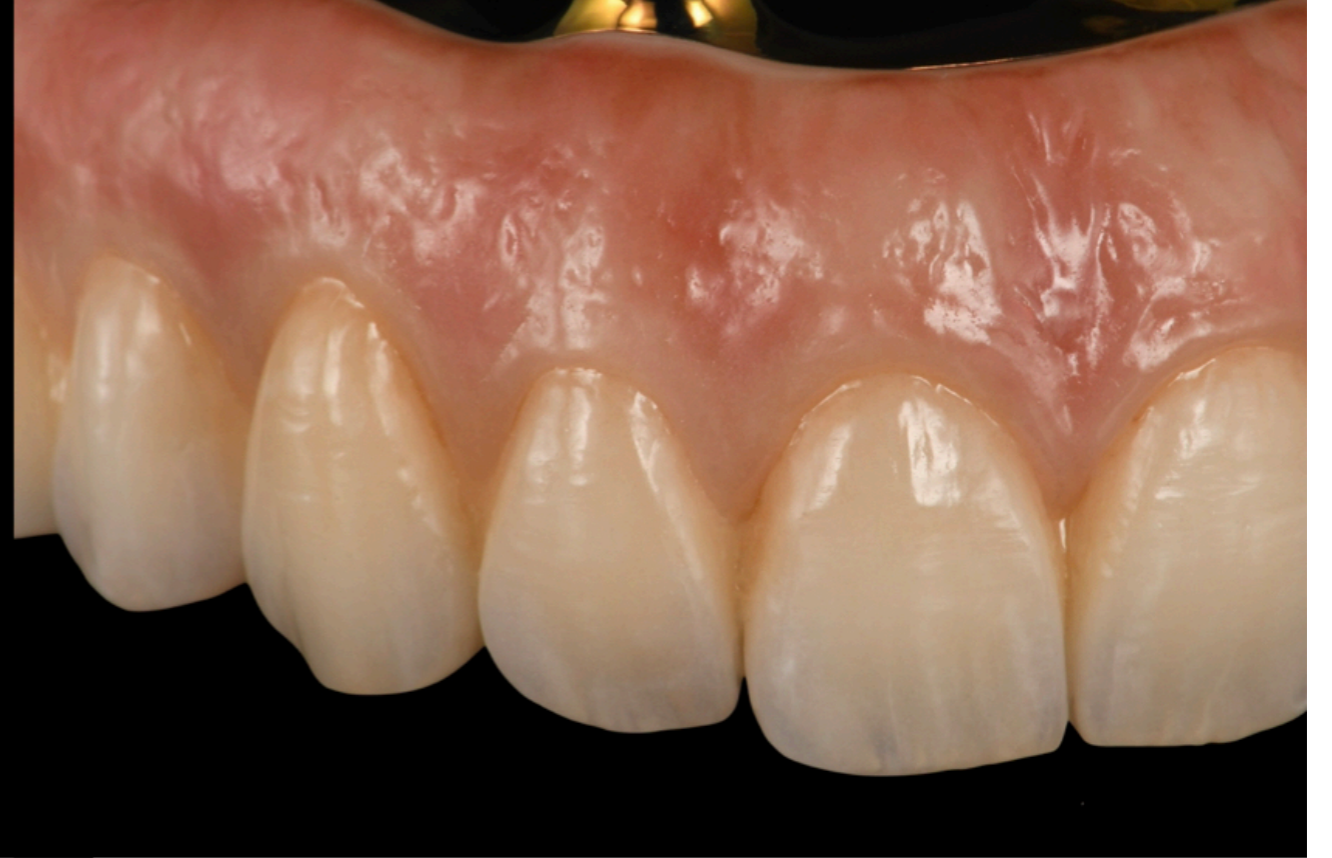
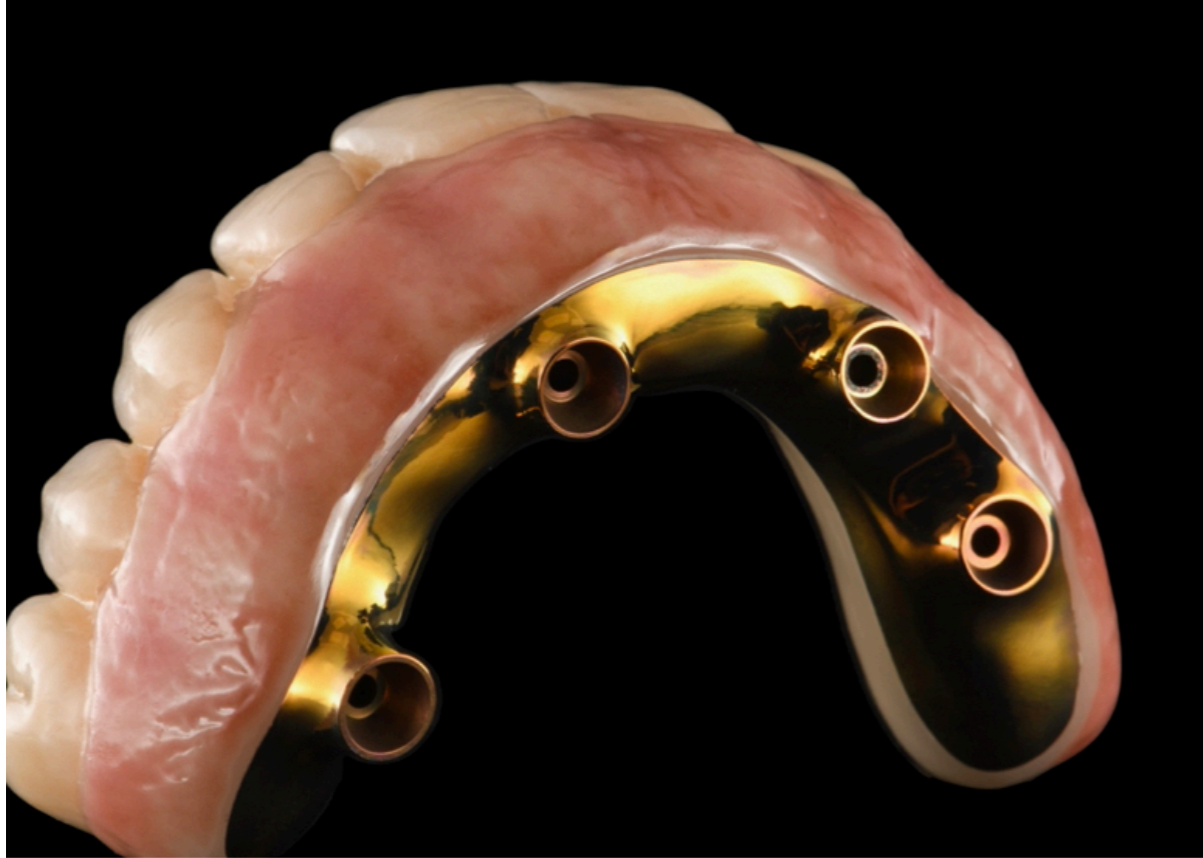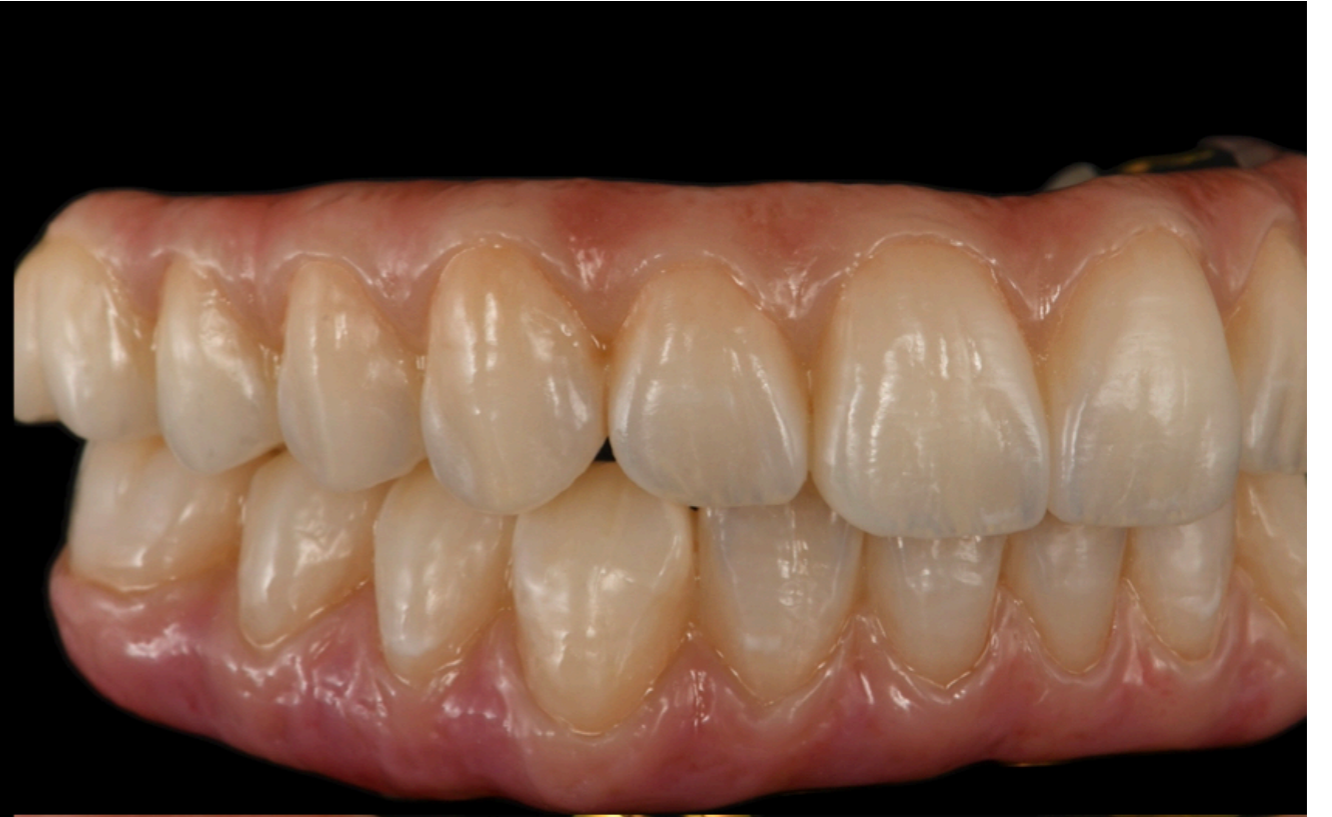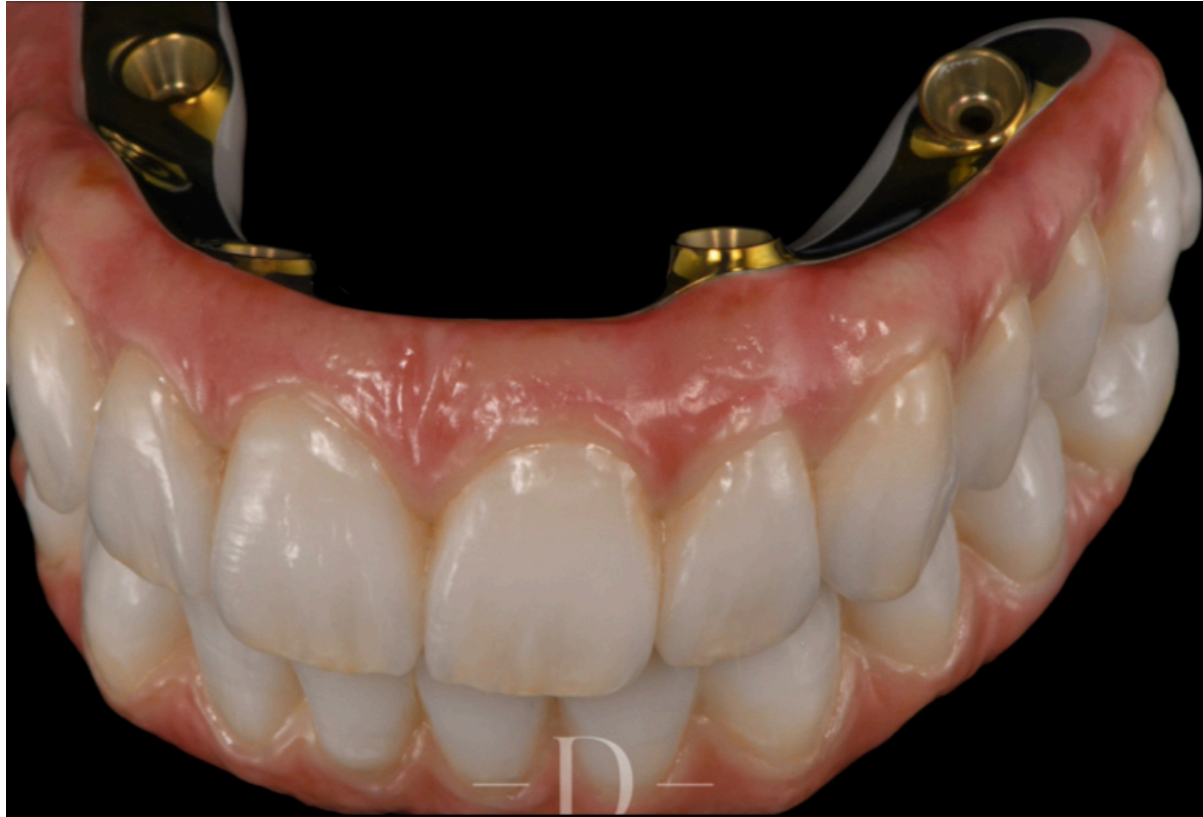Materials

We prefer to use Zirconia as the material for the final restoration.

Working with master ceramists allow us to achieve great aesthetic results.





GET IN TOUCH!



info@drmariorotella.com



[@dr.mariorotella](https://www.instagram.com/dr.mariorotella)